

103

LAPAROSCOPIC SURGERY OF THE KIDNEY

Jay T. Bishoff, MD
Louis R. Kavoussi, MD

Historical Overview

Patient Evaluation and Preparation

Surgical Approaches

- Transperitoneal
- Retroperitoneal
- Hand-Assisted

Simple Nephrectomy

- Indications and Contraindications
- Patient Positioning
- Insufflation and Trocar Placement
- Procedure
- Postoperative Management
- Results

Laparoscopic Transperitoneal Donor Nephrectomy

- Patient Selection
- Operative Preparation
- Patient Positioning
- Procedure
- Alternative Approaches

Renal Biopsy

- Indications
- Patient Positioning
- Procedure
- Postoperative Considerations
- Results

Renal Cystic Disease

- Indications
- Patient Preparation
- Patient Positioning

Procedure

- Autosomal Dominant Polycystic Kidney Disease
- Postoperative Management
- Results

Nephropexy

- Indications
- Procedure
- Results

Pyelolithotomy

Calyceal Diverticulectomy

- Indications
- Procedure
- Results

Laparoscopy for Renal Malignancy

Radical Nephrectomy

- Indications and Contraindications
- Preoperative Evaluation
- Positioning and Trocar Placement
- Procedure
- Results
- Conclusion

Partial Nephrectomy

Laparoscopic Ablative Techniques

- Cryosurgery
- Radiofrequency Interstitial Tissue Ablation

Complications of Laparoscopic Renal Surgery

Conclusions

HISTORICAL OVERVIEW

Since the mid-1990s, there has been an evolution in surgical practice from traditional open approaches toward minimally invasive means of treating operative lesions. Al-

though these changes have been made possible through advances in video technology and instrumentation design, the primary driver has been an increasingly educated patient population seeking less painful means of treatment. Over a century ago, our gynecologic colleagues introduced

Table 103-1. LAPAROSCOPIC NEPHRECTOMY

Author	Approach	Indication	OR Time (Min)	LOH (days)	EBL	Conversion (%)	Complications	Morcellation	Intact
Rassweiler et al, 1993b	Transperitoneal N 24	Benign N 20 Malignant N 4	239 (115-300)	6		16	16% 4/24	83% 20/24	17% 4/24
Kerbl et al, 1994	Transperitoneal N 23 Retroperitoneal N 1	Benign N 20 Malignant N 4	343 (100-700)	4	343 ml	4	20% 5/24	87% 21/24	13% 3/24
Eraky et al, 1994	Transperitoneal N 60	Benign N 60	210 (132-288)	3		10	6% 4/60		
Nicol et al, 1994	Transperitoneal N 5	Benign N 5	180 (120-300)	3				0	100% 5/5
Perez et al, 1994	Transperitoneal N 12	Benign N 12	145 (105-360)	3		8	16% 2/12	0	100% 12/12
Parra et al, 1995	Transperitoneal N 12	Benign N 12	145 (105-360)	4	140	8	16% 2/12	8% 1/12	92% 11/12
Rassweiler et al, 1996	Transperitoneal N 18 Retroperitoneal N 17	Benign N 18 Malignant N 17	206	7 6					
Higashihara et al, 1998		Benign N 51 Malignant N 12	298 (168-428)		239 390	16 8			
Keeley and Tolley, 1998	Transperitoneal N 79 Retroperitoneal N 23	Benign N 76 Malignant N 24	146	4	na	5	18% 18/100	0	100% 100/100
Rassweiler et al, 1998	Transperitoneal N 344 Retroperitoneal N 138	Benign N 444 Malignant N 38	188 (50-400)	5		9 10	6% 29/482 6% 29/482		
Rozenberg et al, 1999	Transperitoneal N 30	Malignant N 17 Benign N 13	116			13	13% 4/30		
Desgrandchamps et al, 1999	Transperitoneal N 14	Benign N 12 Malignant N 2	119 (70-180)	5	50 ml	0	7% 1/14	0	100% 14/14

EBL, estimated blood loss; LOH, length of hospitalization; na, not applicable; OR, operating room.

laparoscopic surgery, primarily as a diagnostic tool. Only recently has it become a practical and acceptable alternative to treat complex surgical diseases.

The development of the laparoscopic pelvic lymphadenectomy for patients with prostate cancer inaugurated the role of laparoscopy in treating urologic lesions (Griffith et al, 1990). In June 1990, Clayman and coworkers at Washington University overcame the barriers to laparoscopic solid organ removal by performing the first laparoscopic nephrectomy (Clayman et al, 1991). In less than 7 hours, an elderly patient with a 3-cm solid renal mass underwent laparoscopic radical nephrectomy through five trocar sites. This accomplishment represents one of the milestones in minimally invasive surgery because it provided the solution for removing a large solid organ without the need for an incision.

Since this report, many institutions have verified the utility of a laparoscopic approach to address benign and malignant diseases of the kidney. Advances in instrument technology and surgical techniques have also allowed complex renal reconstruction to be performed laparoscopically. The result for patients has been markedly less morbidity than open flank surgery. **The benefits of laparoscopic nephrectomy include a lower requirement for pain medication, a shorter hospital stay, reduced convalescence, and a more rapid return to full activity** (Table 103-1) (Copcoat et al, 1992; Kavoussi et al, 1993; Kerbl et al 1993a, 1993b; Rassweiler et al, 1993; Kerbl et al, 1994; Nicol et al, 1994; Perez et al, 1994; Parra et al, 1995; Baba et al, 1996; Doublet et al, 1996; Rassweiler et al,

1996; Rassweiler et al, 1998; Rozenberg et al, 1999; Hermal, et al 1999).

PATIENT EVALUATION AND PREPARATION

Patient preparation for laparoscopic kidney surgery is similar to that for comparable open procedures. **Informed consent must be obtained with a discussion of possible complications including adjacent organ injury and unrecognized bowel injury** (Bishoff et al, 1999). **The patient should be informed that conversion to open surgery might be necessary to safely complete the planned procedure.**

In order for the surgeon to determine any contraindications to laparoscopic surgery or conditions that may alter the laparoscopic approach, the preoperative evaluation must include a careful history and detailed physical examination. **Laparoscopic kidney surgery requires a general anesthetic. Consequently, patients who are not candidates for a general anesthetic should not undergo laparoscopic surgery** (Monk and Weldon, 1992). **Prior abdominal surgery may alter the choice between transperitoneal or retroperitoneal approaches, patient positioning, and the placement site of trocars but is not a contraindication to laparoscopic surgery** (Chen et al, 1998; Cadeddu et al, 1999). Severe cardiac or pulmonary disease may place the patient at risk for complications due to the pneumoperitoneum, which can compromise ventilation and

limit venous return (Arthure, 1970; Hodgson et al, 1970; Nunn, 1987; Lew et al, 1992). Patients with chronic obstructive pulmonary disease may not be able to compensate for hypercarbia induced by the pneumoperitoneum and may require lower insufflation pressures or conversion to open surgery (Monk and Weldon, 1992; Adams et al, 1995).

Laboratory and imaging studies are obtained as indicated. An electrocardiogram and a chest radiograph are obtained before surgery. Pulmonary function studies are performed only in those patients with known respiratory disease or those at high risk based on the history and physical examination. All patients should have their blood typed and screened, and in advanced procedures, cross-matched blood should be available. Bowel preparation varies according to the procedure and the physician's preference.

Anticoagulated patients are managed in cooperation with their primary physician. Patients with bleeding disorders should have 2 to 4 units of packed red blood cells cross-matched before the start of the procedure. Fresh frozen plasma can be given if needed just before the procedure.

Patients with thrombocytopenia can receive platelets 30 minutes before the incision to increase their platelet count to greater than 50,000/ml. Additional platelet transfusion should not be necessary in the absence of symptomatic bleeding. Uremic patients may benefit from desmopressin acetate treatment to improve platelet function.

A preoperative abdominal CT scan is useful in evaluating the location, size, and abnormality of the kidney to be addressed. Areas of perinephric stranding discovered on CT may indicate significant inflammation and adhesions, increasing the chance for conversion to an open procedure. In addition, the scan provides data on the appearance and function of the contralateral kidney. Differential function can be determined with a diethylenetriaminepenta-acetic acid renal scan if needed. Angiography or placement of a ureteral stent is not routinely performed.

SURGICAL APPROACHES

There are three basic laparoscopic approaches for nephrectomy: transperitoneal, retroperitoneal, and hand-assisted.

Transperitoneal

The transperitoneal route is the traditional method used to perform laparoscopic surgery. It results in small incisions and gives latitude in the location of trocar placement. It also affords an optimal working space and facilitates orientation by providing readily identifiable anatomic landmarks.

Retroperitoneal

The retroperitoneal approach mimics traditional open surgery in that the kidney is approached without entry into the peritoneal cavity. However, with the retroperitoneal approach, adipose tissue and the limited working space can

result in difficulty with orientation, visualization, trocar spacing, and organ entrapment. Even though this provides an extraperitoneal operation, injury can occur to intra-abdominal organs, and a hernia can be created during balloon dilatation of the extraperitoneal space (Adams et al, 1996). **Compared with a transperitoneal approach, a retroperitoneal approach results in complication rates, pain medication requirements, lengths of hospital stay, and times to return to normal activity after surgery similar to those of the retroperitoneal route** (McDougall and Clayman, 1996; Rassweiler et al, 1998a). There are patients in whom retroperitoneal access is preferred over the transperitoneal approach. Patients with a history of multiple abdominal surgical procedures or peritonitis may benefit from this approach. Initial retroperitoneal access can be achieved with subsequent opening of the peritoneum as indicated (Cadeddu et al, 1999). Also, patients with abnormality on the posterior surface of the kidney (exophytic cyst or mass) may be better served through retroperitoneal access. **Consequently, the laparoscopic surgeon should be familiar with both transperitoneal and retroperitoneal approaches** (Barreto et al, 1995; Doublet et al, 1996; Gasman et al, 1996; Rassweiler et al, 1998b; Gill and Rassweiler, 1999; Hsu et al, 1999 (see Chapter 100).

Hand-Assisted

In an effort to facilitate learning of laparoscopic techniques, hand-assisted endoscopic techniques have been introduced. The hand-assisted devices offer a bridge between laparoscopic and open surgery and may help surgeons without advanced laparoscopic training. Several devices are available that maintain the pneumoperitoneum while a hand is introduced into the abdomen (Pneumo Sleeve, Dexterity, Inc., Blue Bell, Pennsylvania. Intromit, Medtech, Dublin, Ireland). Hand-assisted laparoscopic surgery permits tactile feedback and allows the hand to assist with dissection, retraction, extraction, and rapid control of bleeding if needed. An incision large enough to allow the surgeon or assistant to insert a hand must be created, and this site can be utilized for organ extraction. **Hand-assisted dissection may be helpful in those patients whose pathologic condition makes laparoscopy more difficult, such as infectious processes or prior surgery.** Multiple series have documented the utility of the hand-assisted technique in simple and radical nephrectomy as well as nephroureterectomy (Keeley et al, 1997; Wolf et al, 1998; Nakada et al, 1997, 1999). Even if the kidney is to be extracted intact, the hand-assisted approach requires a larger incision than that of a complete laparoscopic approach. Moreover, one is limited in where the incision is made. Finally, currently available devices are disposable and add significant cost to the procedure.

SIMPLE NEPHRECTOMY

Indications and Contraindications

Laparoscopic simple nephrectomy is indicated in the treatment of most benign renal diseases in which perma-

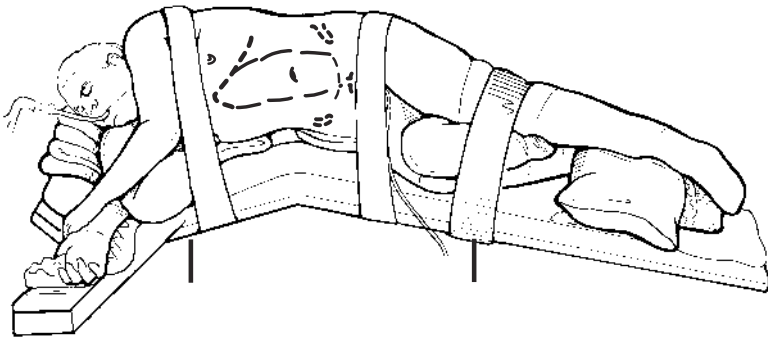


Figure 103-1. The patient is placed in a modified flank position, with the umbilicus over the break in the operating table. This position allows the arms to be placed on the table in a “praying mantis” position or crossed over the chest with two pillows placed between them. (From Bishoff JT, Kavoussi LR [eds]: *Atlas of Laparoscopic Retroperitoneal Surgery*. Philadelphia, WB Saunders, 19xx.).

nent loss of renal function has occurred. **Indications include renovascular hypertension, symptomatic acquired renal cystic disease in dialysis patients, nephrosclerosis, symptomatic patients with autosomal dominant polycystic kidney disease (ADPKD), chronic pyelonephritis, reflux or obstructive nephropathy, multicystic dysplastic kidney, and post-kidney transplantation hypertension** (Fricke et al, 1998).

Several situations require caution when considering a laparoscopic approach. Prior abdominal surgery may result in the formation of intra-abdominal adhesions and increase the possibility of injury to bowel during insufflation, trocar placement, or dissection. The initial entry site in these patients should be away from scars and prior surgical fields. Open trocar placement, a retroperitoneal approach, or may be necessary to minimize access injuries (Hassan, 1971). **Obesity is not a contraindication to laparoscopic transperitoneal or retroperitoneal kidney procedures; however, fatty tissue can make retraction and identification of anatomic structures challenging. Moreover, the increased distance to the operative field may limit trocar placement and require alterations in traditional trocar site selection** (Mendoza et al, 1996; Doublet and Belair, 2000; Jacobs et al, 2000). The weight of the pannus may raise the intra-abdominal pressure and limit the working space. Obese patients are at increased risk for complications from open or laparoscopic surgery (Fazeli-Matin et al, 1999) and may have a greater chance of conversion to open surgery.

Patients with large, dilated loops of bowel from either functional or obstructive ileus should be approached cautiously because the dilated intestinal segments can limit the working space and may be injured during access, dissection, and trocar site closure (Borten, 1986). **Other contraindications include an uncorrected coagulopathy, untreated infection, and hypovolemic shock** (Capelouto and Kavoussi, 1993). Relative contraindications include xanthogranulomatous pyelonephritis and renal tuberculosis (Gupta et al, 1997; Bercowsky et al, 1999), which are associated with a high rate of conversion to open surgery.

Patient Positioning

For transperitoneal laparoscopic nephrectomy, the patient is initially positioned supine for IV access, the induction of general anesthesia, and endotracheal intubation. A bladder

catheter and orogastric tube are placed for decompression of the bladder and stomach during insufflation, trocar placement, and dissection. The umbilicus is placed over the break in the operating table and the patient positioned in a modified lateral decubitus position. The table can be flexed as needed. An axillary roll is placed and padding used to support the buttocks and flank. **The patient is taped in position with multiple strips of wide cloth tape so that the patient will remain securely in place while the table is rolled toward the surgeon to assist with retraction of the bowel** (Fig. 103-1).

The equipment in the operating room is configured to maximize the use of operating room space and to allow all members of the surgical team to view the procedure (Fig. 103-2). During the skin preparation, the entire flank and abdomen are included in case conversion to an open procedure is required.

Insufflation and Trocar Placement

Before trocars are placed, the abdomen is insufflated using a Veress needle. The Veress needle is inserted at the site where the first trocar will be placed and away from previous surgical sites. With the patient in the flank position, the preferred site for initial port placement is at the level of the umbilicus, lateral to the ipsilateral rectus muscle. In the flank position, with anterior displacement of the abdominal wall either manually or by insufflation, the lateral port site will be farthest from the bowel during placement of the Veress needle and the initial port. Once a pneumoperitoneum is established, the first 10- or 12-mm port is placed lateral to the rectus muscle at the level of the umbilicus using a visual obturator to allow entry into the abdomen under direct vision. Once in the peritoneal cavity, the visual trocar is removed and the abdomen is then inspected for any injury due to insufflation and to identify adhesions in areas where the secondary ports will be placed. Remaining trocars are placed under direct vision.

A three-trocar technique is usually utilized to complete the dissection. **A 12-mm trocar is placed lateral to the rectus at the level of the umbilicus; the trocar is used for instrumentation and the passage of staplers to secure and divide hilar vessels. A 10-mm trocar is placed at the umbilicus for the camera and a 5-mm port inserted in the midline between the umbilicus and the xiphoid process.** In obese patients, all trocar sites are

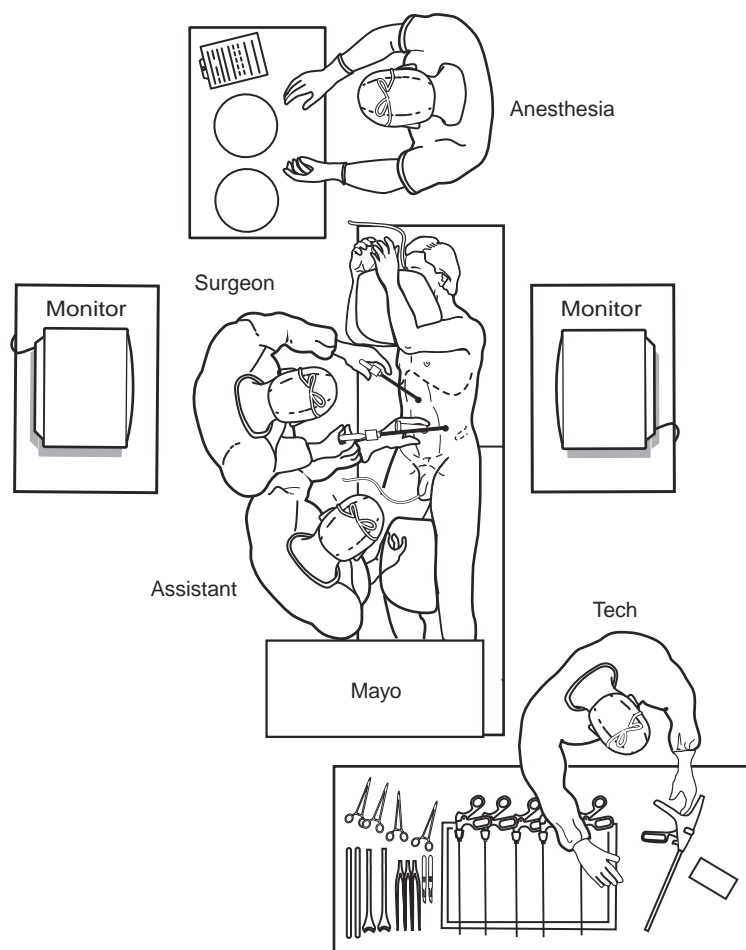


Figure 103–2. The operating room is configured for left nephrectomy. (From Bishoff JT, Kavoussi LR [eds]: *Atlas of Laparoscopic Retroperitoneal Surgery*. Philadelphia, WB Saunders, 19xx.)

moved laterally (Fig. 103–3). Additional trocars for retraction may be needed to complete the hilar dissection or assist with organ entrapment (Fig. 103–4).

Procedure

Reflection of the Colon

For a left nephrectomy, the white line of Toldt is incised from the level of the iliac vessels to above the spleen. The lienocolic ligament should be incised to allow the spleen to fall medially along with the pancreas and the colon (Fig. 103–5). Care must be taken to avoid injuring the diaphragm with this maneuver. During a right-sided nephrectomy, the peritoneal incision is carried cephalad, above the hepatic flexure including the right triangular and right anterior coronary ligaments. Medial traction on the colon reveals colorenal attachments that must be divided to complete the colon dissection (Fig. 103–6).

Dissection of the Ureter

Once the colon has been adequately mobilized, the psoas muscle is seen. When this structure is followed medially, the gonadal vessels are first encountered. These should be swept medially, and the ureter is usually located just deep to these vessels. Peristalsis of the ureter can help differenti-

ate between these two structures. **Once identified, the ureter is elevated and followed proximally to the lower pole and hilum of the kidney. The ureter is not divided at this time because it can be used to help elevate the kidney (Fig. 103–7).**

Identification of the Renal Hilum

With the ureter and lower pole of the kidney elevated, vessels entering the renal hilum can be identified and bluntly dissected using the tip of the irrigator-aspirator. Gonadal, lumbar, and accessory venous branches can be clipped and divided as necessary. **Firm elevation of the lower pole of the kidney assists in identification and dissection of the renal hilar vessels (Fig. 103–8). This is accomplished by gently placing the lateral grasper under the ureter and kidney until it abuts against the abdominal sidewall. It is important to be sure that the grasper is against the muscle and into the renal parenchyma.**

Securing the Renal Blood Vessels

With the hilum on tension from lower pole elevation, gentle dissection with the tip of the irrigator-aspirator reveals the renal vein. By clearing off inferior attachments and inferior lymphatics, one can identify the renal artery.

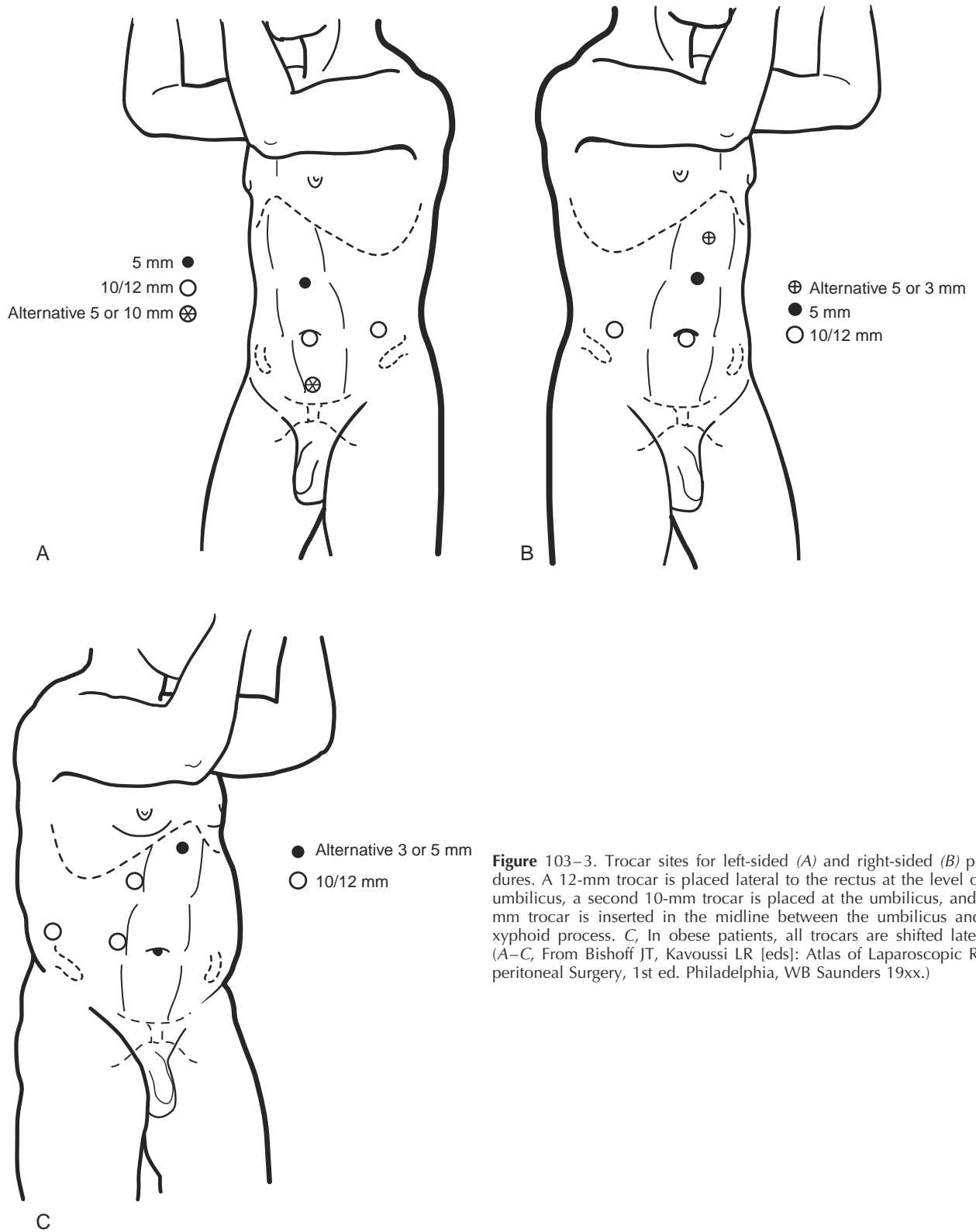


Figure 103-3. Trocar sites for left-sided (A) and right-sided (B) procedures. A 12-mm trocar is placed lateral to the rectus at the level of the umbilicus, a second 10-mm trocar is placed at the umbilicus, and a 5-mm trocar is inserted in the midline between the umbilicus and the xyphoid process. C, In obese patients, all trocars are shifted laterally. (A-C, From Bishoff JT, Kavoussi LR [eds]: *Atlas of Laparoscopic Retroperitoneal Surgery*, 1st ed. Philadelphia, WB Saunders 19xx.)

Figure 103-4. *A*, Additional retraction during left-sided procedures can be accomplished with the use of a blunt instrument passed through a 5- or 10-mm trocar placed above the symphysis pubis. *B*, In right-sided procedures, the liver and bowel can be retracted through a 3- or 5-mm trocar placed in the midline. (*A* and *B*, From Bishoff JT, Kavoussi LR [eds]: Atlas of Laparoscopic Retroperitoneal Surgery. Philadelphia, WB Saunders, 19xx.)

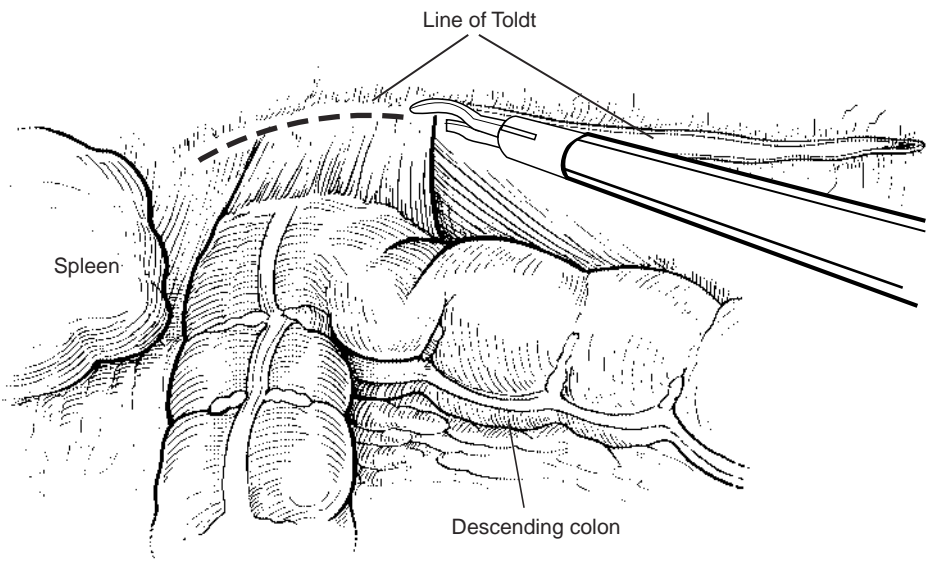
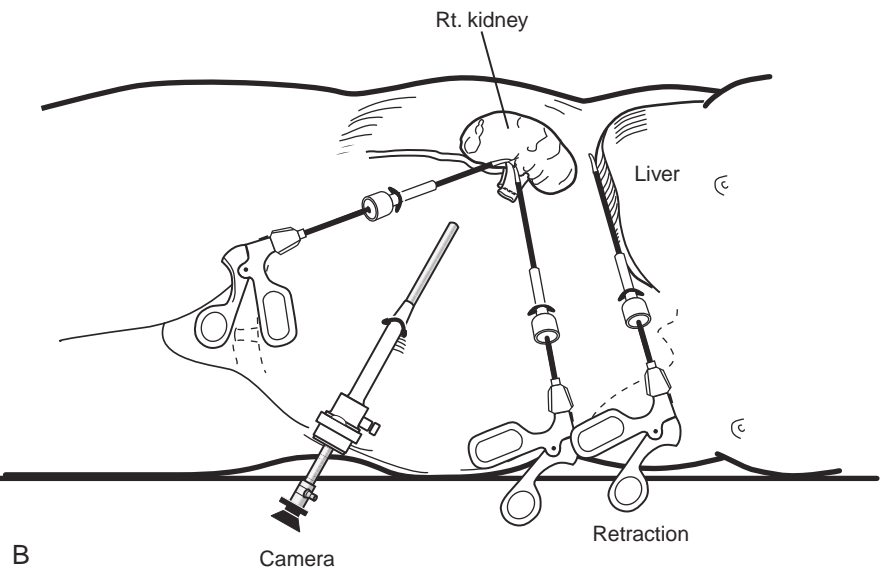
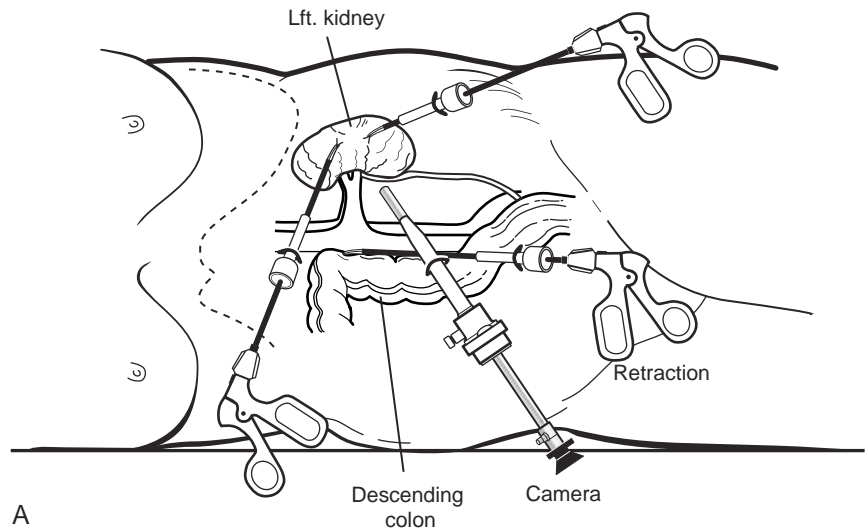


Figure 103-5. Incision of the white line of Toldt allows reflection of the colon. (From Bishoff JT, Kavoussi LR [eds]: Atlas of Laparoscopic Retroperitoneal Surgery. Philadelphia, WB Saunders, 19xx.)

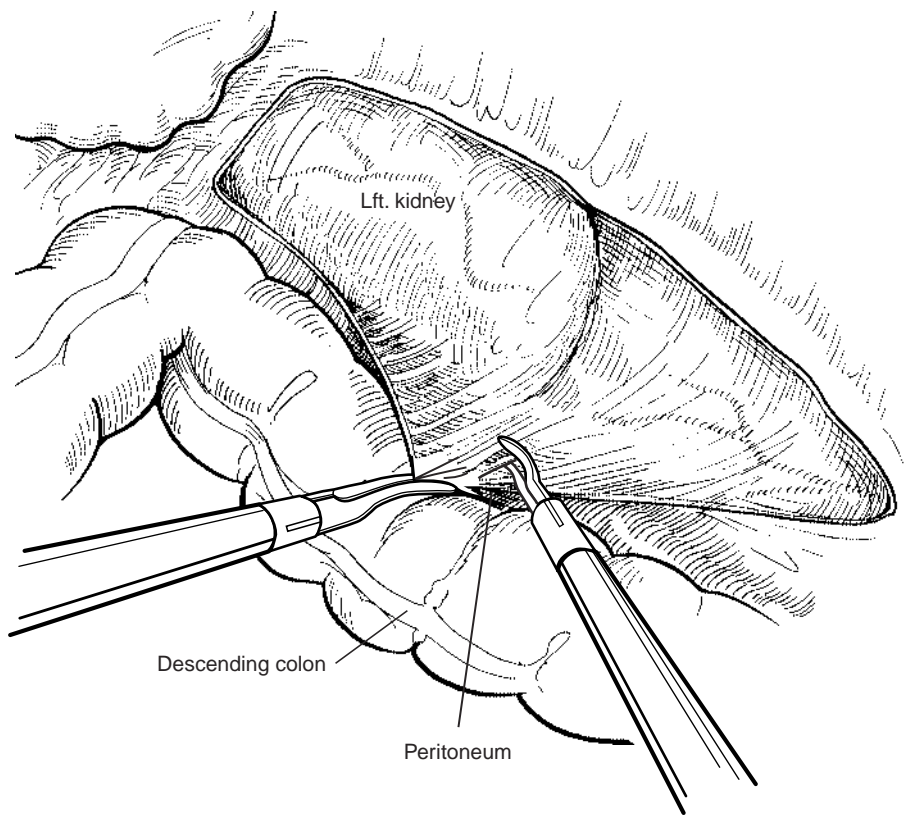


Figure 103–6. Medial traction on the colon helps identify additional colorenal attachments. (From Bishoff JT, Kavoussi LR [eds]: Atlas of Laparoscopic Retroperitoneal Surgery. Philadelphia, WB Saunders, 19xx.)

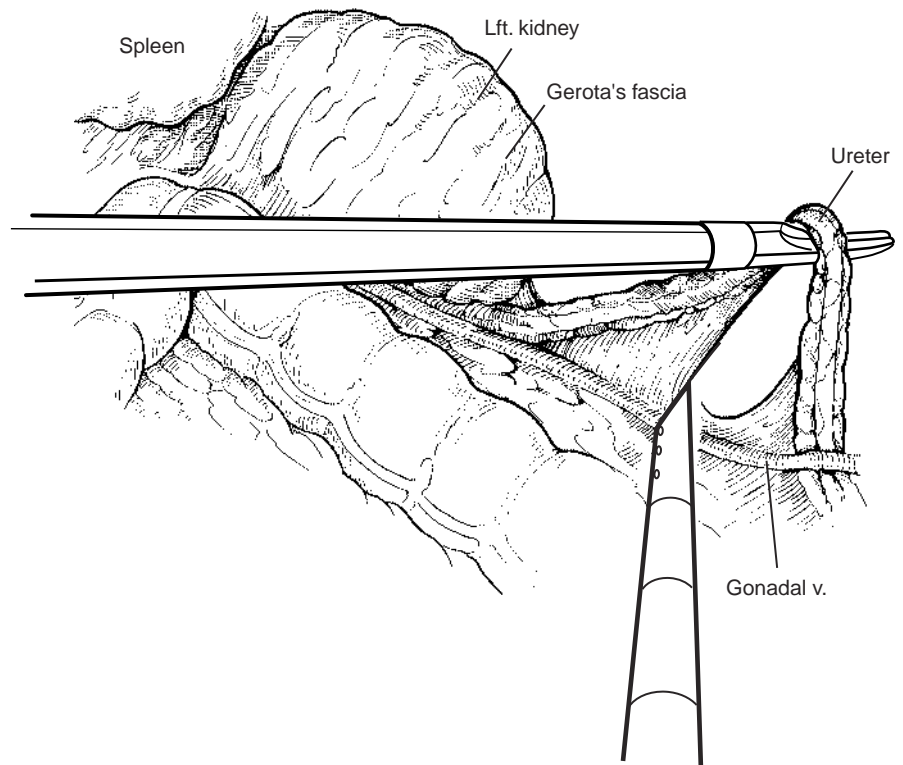


Figure 103–7. A curved dissector, in the left hand, is placed beneath the ureter and used to provide anterolateral elevation. (From Bishoff JT, Kavoussi LR [eds]: Atlas of Laparoscopic Retroperitoneal Surgery. Philadelphia, WB Saunders, 19xx.)

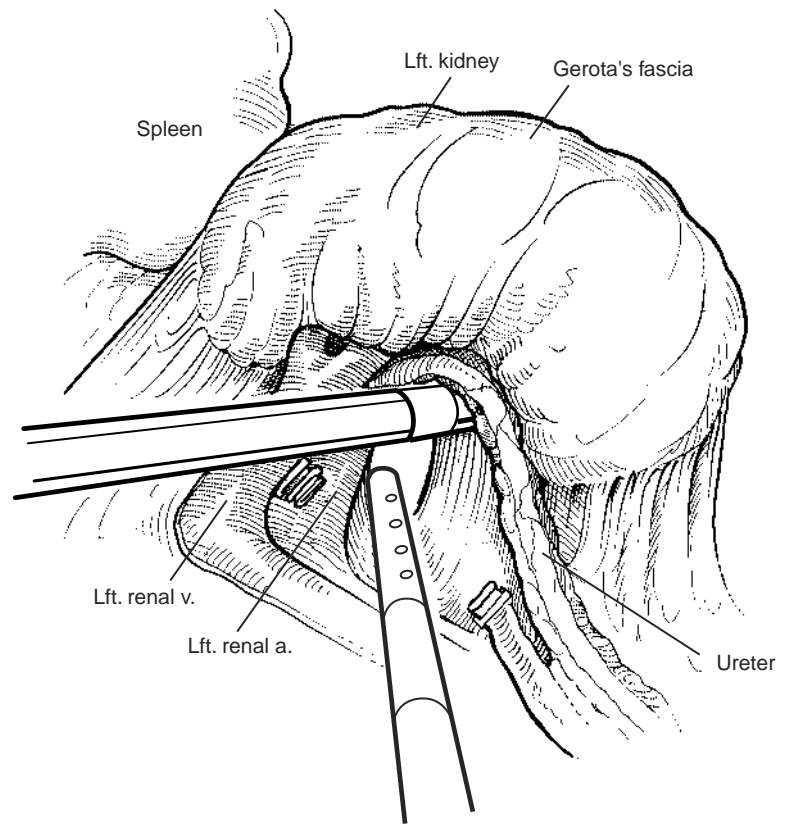


Figure 103–8. The lower pole of the kidney and ureter are firmly retracted anterolaterally, placing the hilum on stretch. (From Bishoff JT, Kavoussi LR [eds]: *Atlas of Laparoscopic Retroperitoneal Surgery*. Philadelphia, WB Saunders, 19xx.)

With an endovascular gastrointestinal anastomosis (GIA) stapler, the artery is divided first, followed by the vein (Fig. 103–9).

Isolation of the Upper Pole

Once all the hilar vessels have been divided, the dissection continues posteriorly and superiorly to the upper pole. The adrenal gland is preserved in cases of simple nephrectomy (Fig. 103–10). This is accomplished by incising Gerota's fascia anteriorly just above the hilum. Gerota's fat is then gently peeled off circumferentially above the upper pole of the kidney. At this point during the dissection, it may be necessary to clip and transect the ureter. This allows the kidney to be rotated anteriorly above the liver (right) or spleen (left) to facilitate incision of the uppermost attachments under direct vision. In cases of extreme fibrosis, a subcapsular nephrectomy can be performed once the artery and vein have been controlled (Moore et al, 1998).

Organ Entrapment

The kidney can be removed through morcellation or intact removal. When morcellation is performed, the specimen should be placed into a sturdy entrapment sac (Urban et al, 1993). This minimizes the risk of rupture during mechanical morcellation of the tissue (Walther et al, 1999; Landman et al, 2000). Alternatively, the kidney can be removed intact through an incision after placement into a sac. The kidney can be worked out of an extended trocar

site or Pfannenstiel incision. For trocar sites greater than 5 mm, it is helpful to place the closure sutures before removing the kidney. Once the sutures are placed, trocars can be reinserted for kidney entrapment and removal.

Postoperative Management

The orogastric tube is removed at the conclusion of the procedure. The patient can begin a diet as tolerated. The Foley catheter should be removed once the patient is comfortably ambulating. The patient is discharged when tolerating a diet. Unrestricted activity can usually be resumed according to the patient's comfort.

Results

The postoperative results of the laparoscopic nephrectomy are comparable to that of open surgery with much less pain and shorter convalescence. **Postoperative pain requirements are approximately four times less than with traditional open incisions. Hospital stays have been decreased by 50%, and the time to full convalescence has been reported to be markedly less than with open removal.** In early series, the mean operative times were greater than 300 minutes. However, with advances in techniques, experience, and equipment, current operative times have decreased dramatically (Kerbl et al, 1994a, 1994b; Nicol et al, 1994; Perez et al, 1994; Parra et al, 1995; Baba et al, 1996; Rassweiler et al, 1996, 1998a).

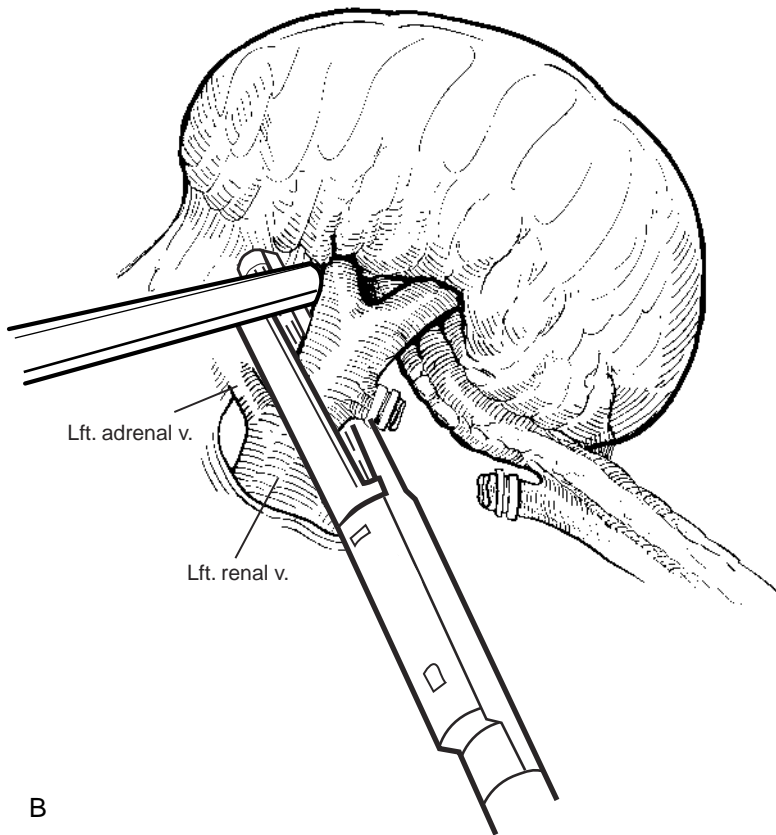
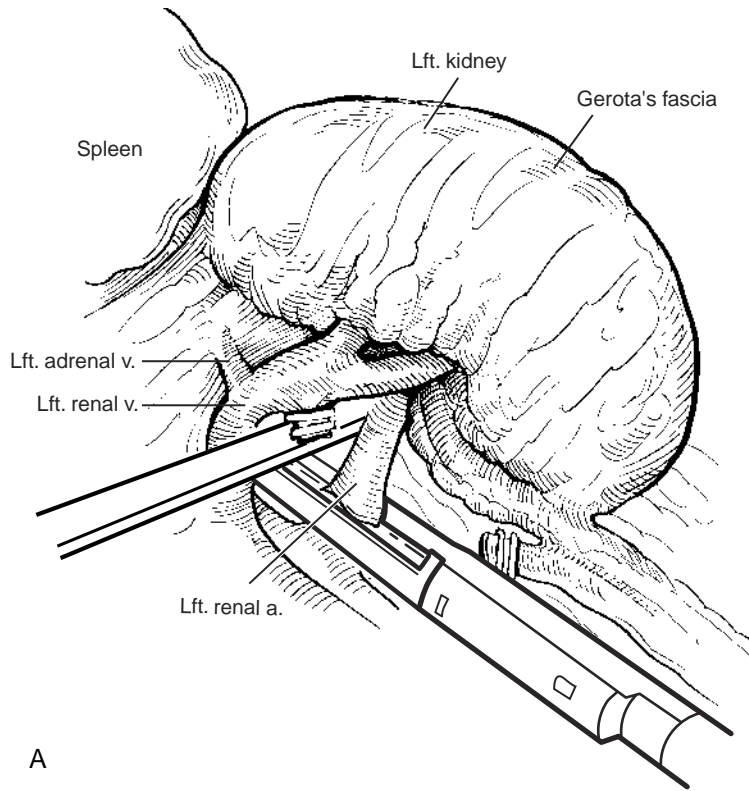


Figure 103-9. *A*, First, the renal artery is stapled using an endovascular gastrointestinal anastomosis (GIA) stapler. *B*, The renal vein is secured lateral to the adrenal vein with the endovascular GIA stapler. (A and B, From Bishoff JT, Kavoussi LR [eds]: Atlas of Laparoscopic Retroperitoneal Surgery. Philadelphia, WB Saunders, 19xx.)

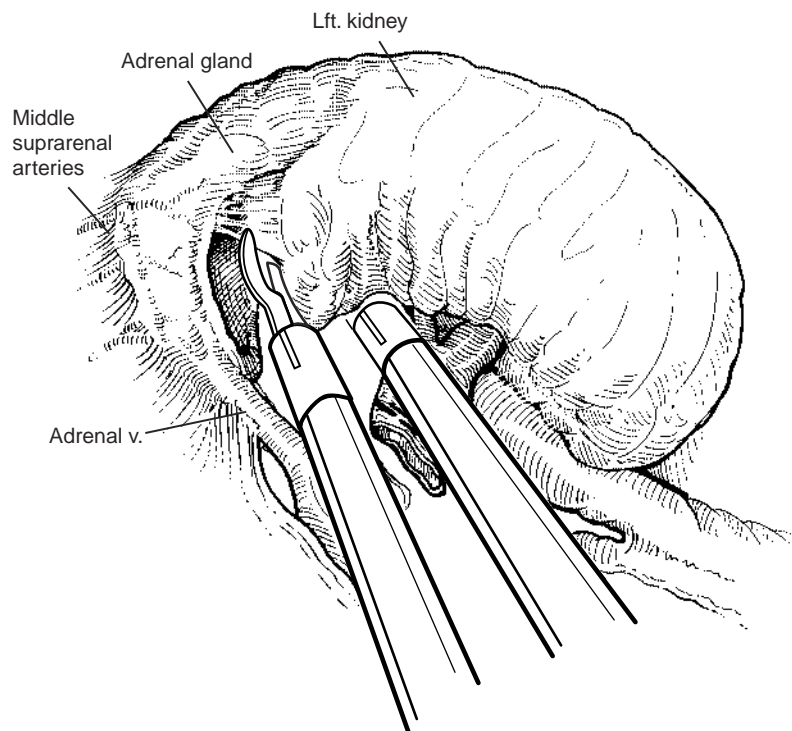


Figure 103–10. The adrenal gland can be preserved during simple nephrectomy. (From Bishoff JT, Kavoussi LR [eds]: *Atlas of Laparoscopic Retroperitoneal Surgery*. Philadelphia, WB Saunders, 19xx.)

LAPAROSCOPIC TRANSPERITONEAL DONOR NEPHRECTOMY

End-stage renal disease affects over one quarter of a million people in the United States. Renal transplantation has had a major impact on the survival and quality of life of those suffering from kidney failure. However, because of a severe shortage of organs, kidney transplantation is not available to all potential candidates. Since 1988, there has been a dramatic rise in the number of patients on waiting lists for renal transplantation, whereas the number of kidneys available has shown only a modest increase (Fig. 103–11).

Living donor kidney transplantation was developed in part to decrease the waiting period. In addition to shorter waiting times, organs obtained from living donors offer many advantages over cadaveric sources. **Living donor graft and patient survival rates are superior to those when cadaveric donor kidneys are used, with an overall graft survival of 93% at 1 year and 84% at 5 years** (United Network for Organ Sharing, 1998). **Living donor transplantation also results in less cold ischemic time and reduced immune suppression requirements and allows optimization of both the recipient and the donor’s medical status** (Hiller et al, 1997; Ratner et al, 1997a).

Laparoscopic living donor nephrectomy was first performed by Ratner and associates in 1995, as a means to diminish the disincentives to organ donation by decreasing the morbidity. **When compared with open nephrectomy for transplantation, the laparoscopic approach results in a shorter hospital stay, lower postoperative analgesic requirements, a faster return to activities of daily living, and an earlier return to employment. Laparoscopic donor nephrectomy has not been shown to have adverse**

affects on allograft function or survival (Ratner et al 1997c, 1998a; Sosa et al, 1998; London et al, 1998; Fabrizio et al, 1999; Kavoussi and Ratner, 2000) (Table 103–2).

Patient Selection

All potential kidney donors undergo medical evaluation in accordance with guidelines published by the American Society of Transplant Physicians (Kasiske et al, 1996; Fishman and Rubin, 1997) to ensure that the donor is left

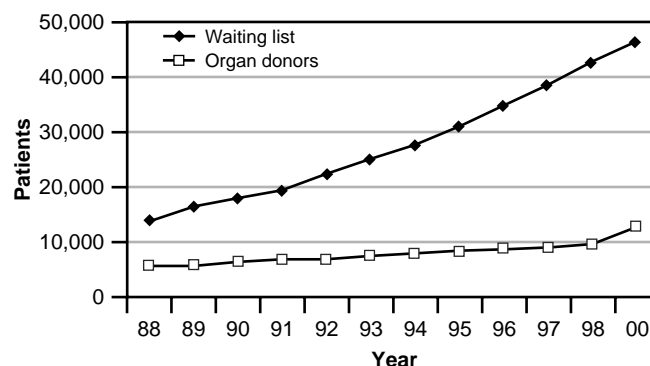


Figure 103–11. Since 1988, the number of patients awaiting kidney transplantation has seen a dramatic increase. The combined number of organs available from living and cadaveric sources has not increased proportionally. (Information from United Network for Organ Sharing (UNOS) and the Division of Transplantation, Bureau of Health Resources and Services Administration: Annual report of the U.S. Scientific Registry of Transplant Recipients and Organ Procurement and Transplantation Network—Transplant Data. Rockville, MD, U.S. Department of Health and Human Services, 1998.)

with adequate renal function after nephrectomy. In addition, the donor's motivation and emotional stability are carefully evaluated. Laparoscopic donor nephrectomy requires accurate radiographic imaging to evaluate the arterial and venous anatomy. **Dual-phase spiral CT with three-dimensional angiography for evaluation of the living donor patients has been shown to adequately depict renal vasculature when compared with standard angiography** (Plat et al, 1997; Dachman et al, 1998; Smith et al, 1998; Del Pizzo et al, 1999). **Careful preoperative evaluation with CT imaging is important to identify the presence of multiple renal blood vessels preoperatively so that they can be identified and preserved during the hilar dissection. The presence of multiple vessels is not a contraindication to laparoscopic donor nephrectomy, but preoperative identification allows the surgeon to anticipate their presence early in the operation** (Kuo et al, 1998).

Additional considerations include the patient's body mass index and prior abdominal surgical procedures. Laparoscopic donor nephrectomy has successfully been performed in obese patients with outcomes similar to those of nonobese patients (Kuo et al, 2000). Patients who have had multiple prior abdominal surgical procedures near the intended operative field may be considered for donor nephrectomy but may be better served with a retroperitoneal or an open approach.

Operative Preparation

Patients are prepared in a manner similar to that of persons undergoing simple nephrectomy; however, they routinely receive 1 to 2 L of IV fluid before insufflation of the abdomen. **Pneumoperitoneum has been shown to decrease renal blood flow; however, vigorous hydration maintains urine output** (London et al, 1998, 2000). **Patients are routinely given a total of 5 to 6 L of crystalloid fluid during the procedure.**

Patient Positioning

To allow access to the anterior abdomen for intact organ retrieval, the patient is placed in the modified flank position with the torso in a 45-degree lateral decubitus position and the table flexed. The hips are maintained flat to facilitate the creation of a Pfannenstiel incision. Wide tape is used to secure the hips and chest to the table, and a safety strap is used to secure the legs. The positioning and security of the patient should be tested by maximally planing the table to the right and left. The operating room configuration is identical to that used in simple nephrectomy (see Fig. 103-2).

Procedure

Insufflation and Trocar Placement

A pneumoperitoneum is established after a Veress needle is passed, and subsequently four transperitoneal laparo-

Table 103-2. OPEN VERSUS LAPAROSCOPIC DONOR NEPHRECTOMY

Results	Laparo- scopic Nx		Open Nx		P value
	N	110	N	48	
Estimated blood loss (ml)	266	174	393	335	.027
Operative time (min)	232	33	183	27	.001
Hospital stay (days)	3.0	0.9	5.7	1.7	.001
Length of time analgesia used (days)					
Oral narcotic agents*		4		12	.001
Acetaminophen		3		17	.001
Resumed oral intake (days)	0.8	0.5	2.6	1.0	.001
Returned to work (wk)	4.0	2.3	6.4	3.1	.003

Nx, nephrectomy.

*Milligrams of morphine equivalents.

From Kavoussi LR, Ratner LE: Laparoscopic donor nephrectomy. *Kidney Int* 2000;57:2175-2186.

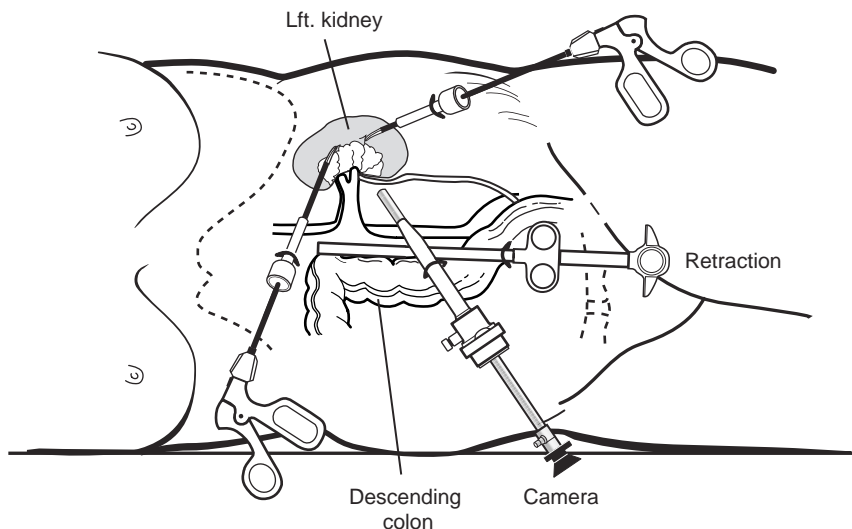
scopic ports are placed. The first 12-mm port is placed at the level of the umbilicus just lateral to the ipsilateral rectus muscle. The second 10/12-mm port is placed at the umbilicus, and a 5-mm port is placed in the midline between the umbilicus and xiphoid, both under direct vision (see Fig. 103-3). To assist with retraction of the colon, visualization of the renal hilum, and kidney extraction, a fourth midline port is placed two fingerbreadths above the symphysis pubis. A 12-mm trocar is passed at this site to create an entry tract through the fascia. The trocar is then removed, and a 15-mm Endocatch device (Autosuture, U.S. Surgical, Norwalk, Connecticut) placed into the abdomen. The Endocatch device is not deployed at this point but instead is used as a blunt retractor. This site can later be incorporated into a 6-cm Pfannenstiel incision for organ retrieval (Fig. 103-12). The umbilical port is used primarily as the camera port. A 30-degree lens is used for visualization during the procedure.

Left-Sided Donor Nephrectomy

The colon is reflected medially by incising the line of Toldt, from the splenic flexure to the level of the iliac vessels. The colorenal ligaments are divided, and Gerota's fascia is exposed and opened to expose the surface of the kidney. Attention is next directed to finding and elevating the upper pole of the kidney (Fig. 103-13). **Renal lobulations can easily be mistaken for the border of the upper pole.** The medial and posterior attachments are gently freed from the upper pole. Dissection of the renal hilum is facilitated by gentle elevation of the upper pole. Gerota's fascia is incised on the medial aspect of the kidney, and the renal vein then becomes apparent. The renal vein is sharply freed from its adventitial attachments, and the gonadal, adrenal, and any associated lumbar branches are identified, clipped, and divided (Fig. 103-14).

The renal artery, which usually lies posterior to the vein, is identified and freed to its origin at the aorta. **Clips are helpful during the dissection to prevent lymphatic leakage but must not be placed where they can interfere with subsequent division of the artery with the GIA stapler.** To prevent and treat vasospasm, the renal artery is

Figure 103–12. A fourth port (10/12-mm) can be placed approximately two fingerbreadths above the symphysis for placement of a blunt grasper or an Endocatch (AutoreSuture, Norwalk, Connecticut) to assist with retraction and organ retrieval. (From Bishoff JT, Kavoussi LR [eds]: *Atlas of Laparoscopic Retroperitoneal Surgery*. Philadelphia, WB Saunders, 2000.)



intermittently bathed with a topical solution of papaverine (30 mg/ml). When the hilar dissection is complete, the patient is given 25 g of mannitol and 20 mg of furosemide (Lasix).

Just below the renal hilum, the gonadal vein is again identified and dissection proceeds medial to this vessel in order to preserve the periureteral tissue and blood supply. **Aggressive dissection of the periureteral tissue to expose the ureter can lead to ureteral strictures in the recipi-**

ent. With gentle elevation of the lower pole, the remaining posterior renal and ureteral attachments are divided with sharp and blunt dissection. The gonadal vessels are ligated and cut where they cross the ureter. The distal ureter is clipped and transected at the level of the iliac vessels. The ureter is divided, leaving the proximal end open for the remainder of the dissection. Lateral attachments to the ureter and kidney are incised.

Before the division of the renal artery and vein, a 6-cm Pfannenstiel incision can be made through the port site created for the Endocatch device. Care is taken to keep the fascia and underlying peritoneum intact in order to maintain the pneumoperitoneum. The patient is given 3000 units of heparin sulfate 5 minutes before division of the vascular pedicle.

The renal hilum is best seen and controlled by placing the forceps between the artery and the vein and gently lifting the kidney. An articulating endovascular GIA stapler is used to divide the renal artery at its origin with the aorta. The renal vein is divided just medial to the aorta (Fig. 103–15). The articulating GIA stapling device allows the head of the stapler to be positioned parallel against the aorta, helping to maximize the length of the vessel.

Once the pedicle is divided, the kidney is placed into the 15-mm Endocatch bag under direct vision by grasping the perirenal adipose tissue with the forceps (Fig. 103–16). **One must ensure that the entire kidney and ureter are inside the extraction bag before closing the bag. Once the kidney is secured, the fascia and peritoneum are opened longitudinally with heavy scissors or cautery and the kidney delivered. The incision is enlarged as needed in order to allow extraction of the kidney without any tension.** After division of the renal vessels, anticoagulation from heparin is reversed by giving the donor protamine sulfate (30 mg).

The fascia is closed with interrupted No. 1 polydioxanone sutures, and a pneumoperitoneum is re-established. The pressure in the abdomen is lowered to 5 mm Hg. At a low intra-abdominal pressure, the transected vessel stumps and the trocar sites are carefully inspected for bleeding. The carbon dioxide is evacuated from the abdomen to prevent referred pain postoperatively, and all 12-mm trocar sites

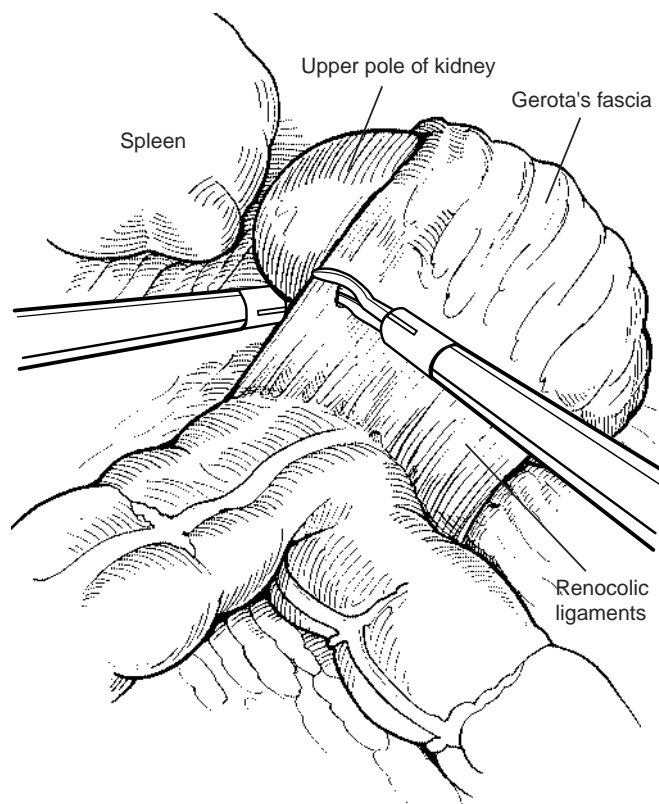


Figure 103–13. The renocolic attachments to the kidney are divided, and the upper pole of the kidney is located and elevated. (From Bishoff JT, Kavoussi LR [eds]: *Atlas of Laparoscopic Retroperitoneal Surgery*. Philadelphia, WB Saunders, 2000.)

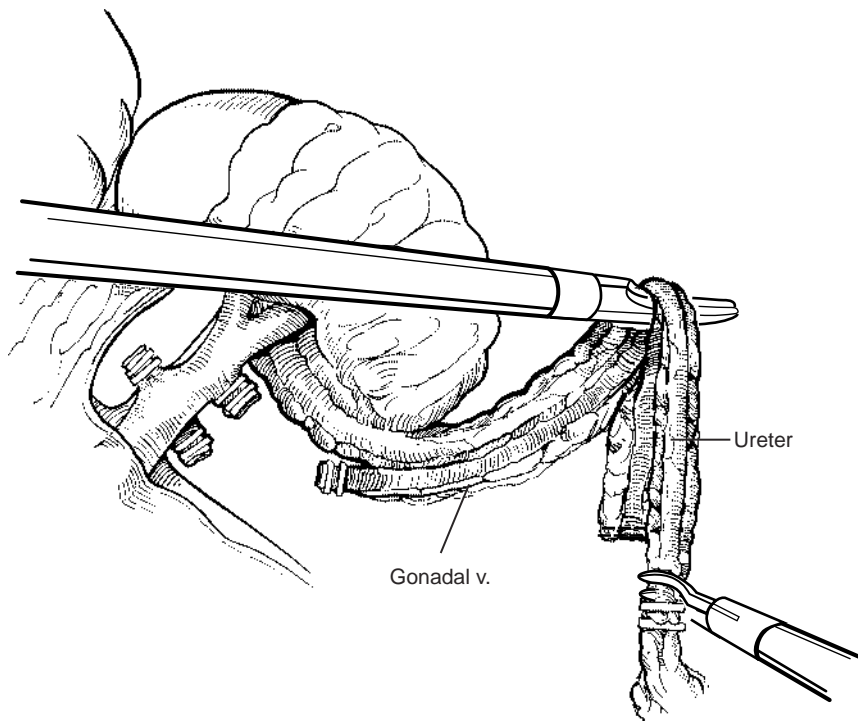


Figure 103–14. After the renal vein is exposed, the gonadal, lumbar, and adrenal veins are clipped and divided. The divided gonadal vessel is left with the ureter to preserve the blood supply. (From Bishoff JT, Kavoussi LR [eds]: Atlas of Laparoscopic Retroperitoneal Surgery. Philadelphia, WB Saunders, 2000.)

are closed. The skin incision and trocar sites can be closed with 4-0 polyglactin (Vicryl) sutures.

Right-Sided Donor Nephrectomy

Right-sided nephrectomies are performed when indicated by the relative renal function or vascular configuration.

The right side is more technically difficult to approach because of the short renal vein and need for liver retraction to allow dissection of the upper pole (Fabrizio et al, 1999). The application of the endo-GIA stapler on the right renal vein can result in a loss of 1 cm of length (Ratner et al, 1998a).

During a right-sided donor nephrectomy, the midline

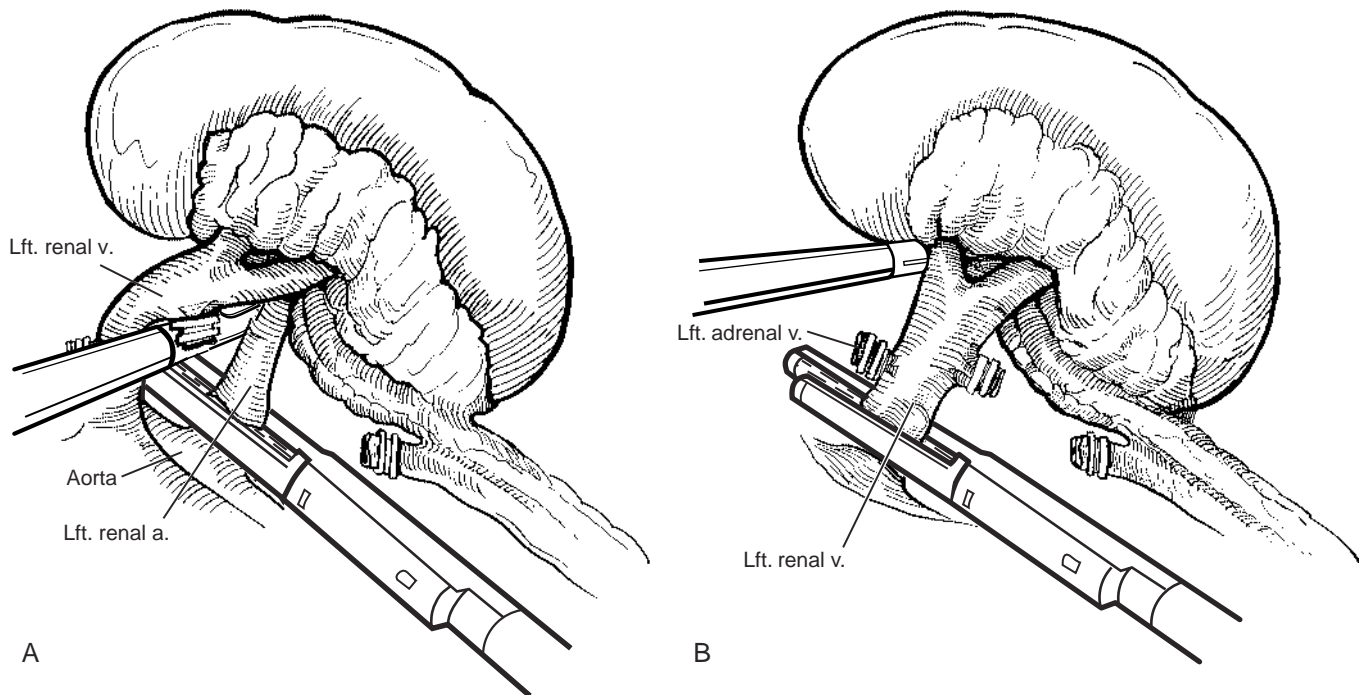


Figure 103–15. Division of the vascular pedicle. *A*, The renal artery is divided against the aorta to provide maximal length. *B*, Division of the renal vein proximal to the adrenal vein. (*A* and *B*, From Bishoff JT, Kavoussi LR [eds]: Atlas of Laparoscopic Retroperitoneal Surgery. Philadelphia, WB Saunders, 2000.)

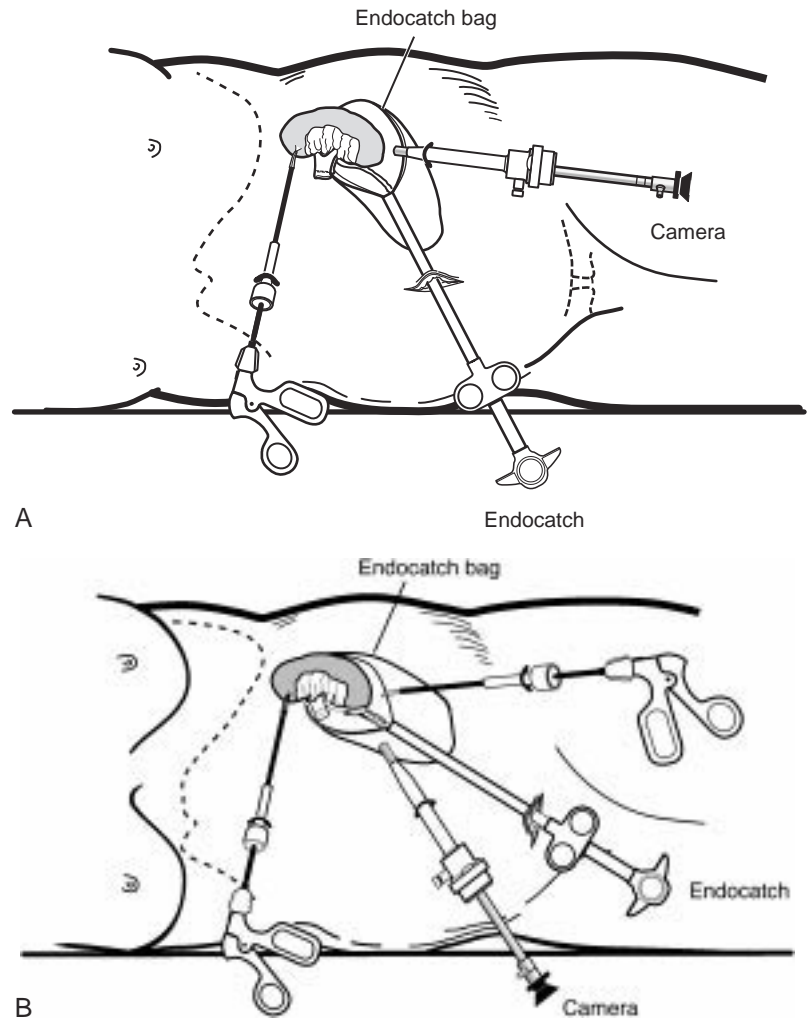


Figure 103-16. *A*, The periumbilical approach for harvesting the kidney. *B*, The kidney may also be removed through a Pfannenstiel incision, using the low midline access site. (*A* and *B*, From Bishoff JT, Kavoussi LR [eds]: *Atlas of Laparoscopic Retroperitoneal Surgery*. Philadelphia, WB Saunders, 2000.)

port between the xiphoid and umbilicus is moved cephalad and increased to 12 mm because it will be extended laterally to allow open ligation of the vessels. The dissection of the right upper pole and renal hilum requires retraction of the liver edge through a separate trocar site. Exposure of the short right renal vein at the level of the vena cava is only accomplished after the duodenum is reflected medially.

After the kidney, renal hilum, and ureter are completely freed of attachments, the ureter is transected. A 6- to 8-cm right upper quadrant transverse incision is made over the renal hilum. A self-retaining retractor is used for exposure. The renal artery is divided between No. 0 silk ties or clips, and the renal vein is divided after placement of a vascular clamp across the inferior vena cava, allowing maximal length on the renal vein. The vena cava can be closed with 4-0 Prolene or using the VCS (Autosuture, Norwalk, Connecticut) clip applicator.

Alternatively, through mobilization of the vena cava, an articulating GIA stapler may be used to transect the vessels, and the procedure can be completed as a left-sided nephrectomy. Ligation of lumbar vessels frees the vena cava to permit an adequate cuff for an anastomosis to be obtained.

Results

DONOR

When laparoscopic and open surgical approaches for kidney donation are compared, the laparoscopic route offers the donor several significant benefits (see Table 103-2). **Compared with open donor nephrectomy, the laparoscopic approach has been shown to significantly decrease blood loss, readmission rates, the time to resume oral intake, analgesic requirements, the length of hospital stay, the time to full activity, and the time to return to work** (Hiller et al, 1997; Ratner et al, 1997a, Ratner 1997b, Ratner 1999; Flowers et al, 1997; London et al, 1999; Sasaki et al, 1999; Jacobs et al, 2000a; Kavoussi et al, 2000).

Donor complications seen in the laparoscopic approach compare favorably with those reported in open series (Ruiz et al, 1980; Weinstein et al, 1980; D'Alessandro et al, 1995; Waples et al, 1995; Dunn et al, 1996; Johnson et al, 1997; Foss et al, 1998). Major complications in laparoscopic series have been reported in 2% to 4% of patients, with approximately 2% requiring conversion to open nephrectomy. Approximately 2% to 4% of patients undergoing donor nephrectomy require transfusion

Table 103–3. DONOR COMPLICATIONS*

Major	
Postoperative retroperitoneal bleed (that required transfusion)	2
Stapler malfunction (that resulted in emergent open conversion)	1
Epigastric artery injury	1
Bowel injury	1
Pneumonia	1
Incisional hernia	1
Minor	
Thigh paresthesia (transient)	7
Superficial wound infection or seroma	5
Urinary tract infection	2
Mucus plug or atelectasis	1
Prolonged ileus	1
Epididymitis	1

*Data from initial 175 patients at Johns Hopkins University. From Kavoussi LR, Ratner LE: Laparoscopic donor nephrectomy. *Kidney Int* 2000;57:2172–2186.

of blood products. Donors return to work an average of 16 to 27 days after laparoscopic surgery compared with 45 to 52 days for patients undergoing open donor nephrectomy (Fabrizio et al, 1999; Hensman et al, 1999; Jacobs et al, 1999; Sasaki et al, 1999; Jacobs et al, 2000a, 2000b).

Ratner reported an overall complication rate of 14% and a major complication rate of 4% in 175 laparoscopic donor nephrectomy procedures. There were three conversions (1.7%) to open surgery for bleeding that could not be controlled laparoscopically, and six patients (3.4%) were transfused in the postoperative period (Table 103–3). **The laparoscopic donor surgeon should consider conversion to open surgery in cases of uncontrolled bleeding, injury to adjacent organs, complex unexpected vascular anatomy, prolonged renal warm ischemia, and failure to progress the dissection leading to prolonged insufflation times.**

Because of longer operative times compared with open surgery and specialized equipment, the cost is approximately \$600 more than that of open donor nephrectomy. However, when the overall cost to the donor patient, family, employer, and society are considered, the more rapid recovery and return to work offered through laparoscopic donation yields an actual cost savings of \$4000 per patient (Kavoussi and Ratner, 2000).

RECIPIENT

Concerns that the prolonged pneumoperitoneum could cause decreased renal blood flow, transient renal ischemia, acute tubular necrosis, and impaired allograft function have not been supported by long-term studies (McDougall et al, 1996; Chiu et al, 1995). **Immediate graft function and long-term survival rates are similar for the laparoscopic and open groups** (Fabrizio et al, 1999; London et al, 1999, London 2000; Truman et al, 1999). In a 2000 review (Kavoussi and Ratner, 2000; Ratner et al, 2000), 110 kidneys harvested laparoscopically were compared with 48 open removals; graft survival at 1 year was 93.5% and 91.1% and recipient survival was 100% and 97%, respectively. Biopsy proven rejection oc-

Table 103–4. RECIPIENT MORBIDITY

	Laparo- scopic Nx N 110	Open Nx N 48	P value
Hospital stay (median days)	7	7	NS
Ureteral complications	10 (9.1%)	3 (6.3%)	NS
Vascular thrombosis	3 (2.7%)	2 (4.2%)	NS
Rejection during first month	32 (29.0%)	15 (31.2%)	NS
Dialysis during first week	7 (6.4%)	3 (6.2%)	NS

NS, not significant; Nx, nephrectomy. From Kavoussi LR, Ratner LE: Laparoscopic donor nephrectomy. *Kidney Int* 2000;57:2172–2186.

curing within 90 days was seen in 30% of the laparoscopic and 35% of the open nephrectomies (Table 103–4). There were no demographic or clinical differences between the two groups.

Compared with open donor nephrectomy, the mean serum creatinine level has been reported to be higher in the laparoscopic group up to 1 month after transplantation. However, at 3, 6, and 12 months, there were no differences between the two approaches. At 12 months, the mean creatinine clearance in recipients of kidneys from laparoscopic and open procedures was the same (66 ml/min) (Table 103–5). One year after transplantation, the mean serum creatinine level of the laparoscopic group has been reported to be lower than in open nephrectomy series (Shaffer et al, 1998; London et al, 1999; Nogueira et al, 1999; Kavoussi and Ratner 2000; Ratner et al, 2000).

Bartlett and colleagues (1999) reported on 295 laparoscopic donor nephrectomy procedures and also found the 12-month survival to be equal to that of kidneys harvested from open nephrectomy patients. **The long-term graft survival, at 1 and 2 years, is the same for both open and laparoscopic groups (98% and 97%, respectively)** (Nogueira et al, 1998; Ratner et al, 1998c; Bartlett et al, 1999; Hensman et al, 1999; Jacobs et al, 1999; Philosophie et al, 1999; Truman et al, 1999).

In a comparison of 95 open donor nephrectomy and 95

Table 103–5. ALLOGRAFT REJECTION AND FUNCTION

	Laparo- scopic Nx N 110	Open Nx N 48	P value
Rejection within 90 days	33 (30%)	17 (35.4%)	0.42
Onset of rejection (median days after Tx)	8.0	8.5	0.48
Pathologic findings			
Glomerulitis	0.6 1.0	0.2 0.5	0.24
Cellular infiltrate	2.1 0.8	2.0 0.8	0.77
Tubulitis	1.9 1.0	1.8 1.0	0.68
Intimal arteritis	0.5 0.7	0.5 0.8	0.63
Banff diagnostic category score (1–4)	2.8 1.3	2.7 1.8	0.56
Creatinine clearance at 12 mos (ml/min)	66	66	0.78

Nx, nephrectomy; Tx, transplantation. From Kavoussi LR, Ratner LE: Laparoscopic donor nephrectomy. *Kidney Int* 2000;57:2172–2186.

laparoscopic donor nephrectomy recipients, Edey and associates (1999) reported greater serum creatinine levels at days 2 to 5 for the laparoscopic group. By day 6, there was no difference between the two groups. At 3 and 12 months, the serum creatinine levels were lower in the laparoscopic group than in the open series. Acute rejection occurred in 32% of kidneys from open procedures and 15% of laparoscopic allografts. Three surgical graft failures and five ureteral complications were seen in each group.

The incidence of surgical complications in recipients appears to be equivalent between the two groups (Kavoussi and Ratner, 2000). **Early reports of laparoscopic donor nephrectomy cited ureteral complications ranging from 9% to 15%. Disruption of the ureteral blood supply through aggressive dissection and exposure of the ureter was the cause in most cases. Occasionally, the ureter had been trapped outside the bag retrieval device during extraction. Changes in ureteral dissection, in which the gonadal vein is divided at the renal vein and then dissected laterally with the ureter, have preserved the periureteral blood supply and have resulted in a decrease in ureteral complication rates to less than 3%** (Kuo et al, 1998, Ratner et al, 1999; Dunkin et al, 2000; Jacobs et al, 2000; Kavoussi and Ratner, 2000).

Alternative Approaches

Retroperitoneal

The retroperitoneal approach has been used for the donor procedures (Rassweiler et al, 1998; Ishikawa et al, 1998). **Compared with the transabdominal working space, there is less room in the retroperitoneum for organ manipulation and entrapment.** The kidney is removed through a 6- to 8-cm flank incision.

Hand-Assisted

The success of laparoscopic living donor nephrectomy in experienced hands has encouraged many institutions to offer this technique. One limitation is the need for advanced laparoscopic training and a case volume sufficient to maintain expertise in performing renal surgery. Hand-assisted laparoscopic donor nephrectomy has been an alternative developed to bridge the gap between laparoscopy and open surgery. **The warm ischemic time and operative times have been shown to be improved over the laparoscopic approach, and there is no difference to the donor in terms of the length of hospital stay and the time to full recovery** (Nakada, 1997; Slakey et al, 1999).

Wolf and coworkers (2000) compared 10 hand-assisted, left-sided laparoscopic donor nephrectomies with 40 open donor surgeries. They demonstrated a longer operative time with the laparoscopic hand-assisted approach compared with open surgery (mean 215 vs. 95 min, respectively) and a shorter hospital stay for the laparoscopic group (mean 1.8 vs. 2.9 days). The mean warm ischemic time was 2.9 minutes in the laparoscopic group and not reported in the open series. There were no differences between groups in terms of donor complications, allograft function, and ureteral problems. The mean hospital costs were 23% greater

in the laparoscopic group ($P = .005$), with the hand-assisted device accounting for 11% of the operative costs. The cost savings from slightly shorter operating room times were offset by the costs of disposable items.

RENAL BIOPSY

Renal biopsy is an important component in the assessment of proteinuria or unexplained medical disease of the kidney. Histologic information is often pivotal in making treatment decisions and providing prognostic information (Morel-Maroger, 1982; Gault and Muehrcke, 1983; Manoligod et al, 1985).

Ultrasound-guided percutaneous needle biopsy, under local anesthesia, is the current standard for obtaining renal tissue. Unfortunately, there is a 5% rate of significant hemorrhagic complications, and as many as 5% to 20% of cases yield inadequate tissue for accurate diagnosis (Wickre and Golper, 1982). When percutaneous biopsy fails or is considered to have a high risk, patients are referred for surgical renal biopsy. This allows hemostasis to be achieved under direct vision and provides the pathologist with adequate tissue to make a diagnosis. Laparoscopic renal biopsy offers the advantages of open biopsy with the decreased morbidity of a two-port outpatient procedure.

Indications

Renal biopsy under direct vision is indicated in three primary categories of patients: failed percutaneous needle biopsy, anatomic variations, and a high risk of bleeding complication. Factors that may make a patient unsuitable for percutaneous biopsy include morbid obesity, multiple bilateral cysts, a body habitus that makes localization impossible, and a solitary functioning kidney. Laparoscopic renal biopsy is contraindicated in those patients with an uncorrectable coagulopathy, uncontrolled hypertension, or an inability to tolerate general anesthesia. Renal imaging with CT or ultrasonography is performed to determine any abnormality, such as renal cysts or solitary kidney, that may alter the choice of kidney for biopsy.

Patient Positioning

The patient is placed in the full flank position with the umbilicus over the table break. The table is fully flexed to help increase the distance between the ribs and the iliac crest. Grounding pads for electrocautery and the argon beam coagulator are placed on the exposed upper thigh.

Procedure

Retroperitoneal Access

A 10-mm transverse incision is made in the skin midway between the iliac crest and the tip of the 12th rib in the posterior axillary line. A 0-degree lens and visual obturator

obturator is removed, leaving behind the 10-mm trocar. Carbon dioxide insufflation is begun at a pressure of 20 mm Hg. Blunt dissection, using only the laparoscope, is initially used to create a retroperitoneal working space. Anteriorly, the peritoneum is swept medially, exposing the underside of the transversalis fascia (Fig. 103–17). Once anterior dissection has mobilized the peritoneum medially, a 5-mm port is placed in the anterior axillary line at the same level as the first port (Fig. 103–18).

Kidney Exposure and Biopsy

The lower pole of the kidney is located and Gerota's fascia opened using blunt and sharp dissection. **In anatomically challenging patients such as those who are morbidly obese, preoperative transcutaneous or intraoperative ultrasonography may be valuable in localizing the kidney** (Chen et al, 1997). Once Gerota's fascia is incised, the perirenal fat is swept aside to expose an approximately the lower pole. A 5-mm biopsy forceps is used to take several cortical samples (Fig. 103–19).

Hemostasis and Closure

Hemostasis is obtained with the argon beam coagulator. During activation of the argon beam, it is important to open an insufflation port, because the flow of argon gas can markedly increase the intra-abdominal pressure. Once adequate hemostasis is believed to be achieved, the insufflation pressure is lowered to 5 mm Hg for at least 5 minutes and the entire retroperitoneum inspected for hemostasis. Persistent bleeding from the biopsy site is treated with repeated argon beam coagulation. Once hemostasis has been confirmed under low pressure, oxidized cellulose (Surgicel) is packed into the biopsy site and direct pressure is applied. The skin incisions are irrigated, inspected for hemostasis, and closed with a 4-0 absorbable subcuticular suture.

Postoperative Considerations

The length of hospital stay depends on the patient's health status. Specific attention is given to blood pressure control. **Care must be taken in patients requiring postoperative resumption of anticoagulation. Usually, patients can resume their usual oral warfarin dose 24 to 48 hours after surgery. Patients who require IV heparin must be followed very closely to ensure that they do not become supratherapeutic.**

Most nonhospitalized patients can be discharged the same day as the biopsy. They are given oxycodone-acetaminophen for pain control and can resume activity as tolerated.

Results

A report of 32 consecutive patients who underwent laparoscopic renal biopsy showed 100% success in obtaining adequate tissue for histopathologic diagnosis (Gimenez et al, 1998). The mean blood loss was 26 ml, the operative

time was 1.5 hours, and the hospital stay was 1.7 days. Sixteen patients (50%) were treated as outpatients. Complications included one inadvertent biopsy of the spleen without consequence and one 300-ml hematoma that resolved without a need for intervention. The overall complication rate was 6% (2 of 32). One patient on high-dose steroid therapy developed a perforated peptic ulcer and died seven days after surgery. **Hemorrhage is the most common major complication associated with laparoscopic renal biopsy. Careful resumption of anticoagulation is mandatory. The cause of a persistent decline in hematocrit or symptoms of hypovolemia should be evaluated by CT.**

In another series, of 17 patients, a balloon was inserted into the retroperitoneum to create the working space (Gaur et al, 1994). Adequate renal tissue for diagnosis was obtained in each case. The mean operative time was 35 minutes, excluding anesthesia time, with a range of 20 to 45 minutes. Fifteen patients were discharged within 24 hours, and two patients remained hospitalized for 4 days. Complications were seen in 11% of the patients (2 of 17), including severe bleeding requiring conversion to an open procedure and one patient with marked gross hematuria days.

RENAL CYSTIC DISEASE

Renal cysts are present in approximately one third of patients older than 50 years, and few require surgical intervention (Hoenig et al, 1997; Wolf, 1998). **Patients with pain, infection, or obstruction may need cyst excision.** Moreover, with the advent of CT and ultrasonography, the detection of indeterminate renal masses and complex renal cysts has become a frequent occurrence. Classification schemes have been devised based on CT criteria to help surgeons determine whether further diagnostic or therapeutic maneuvers are necessary (Table 103–6) (Bosniak and Morton, 1986). Unfortunately, imaging studies are not always diagnostic, and surgical removal may be needed to exclude the possibility of malignancy.

In addition, approximately 600,000 individuals suffer from ADPKD. The clinical course of ADPKD is usually dominated by symptoms of abdominal fullness or pain and may require surgical treatment for symptomatic relief. End-stage ADPKD may occasionally require bilateral or unilateral nephrectomy for the treatment of cyst complications, bleeding, infection, or pain.

Indications

Needle aspiration with sclerosis of symptomatic renal cysts is usually the first line of therapy. However, it is not always effective and can pose a risk of fibrosis when perihilar cysts are approached (Wehle and Grabstald, 1986; Hulbert et al, 1988; Lifson et al, 1998; McDougall, 1998; Santiago et al, 1998). Renal cysts may also obstruct the collecting system, compress renal parenchyma, or spontaneously hemorrhage, inducing pain and hematuria. In addition, they may become infected, cause obstructive uropathy, and cause hypertension. The laparoscopic approach offers a minimally invasive modality to decompress cysts under direct vision. Complex cysts can also be ex-

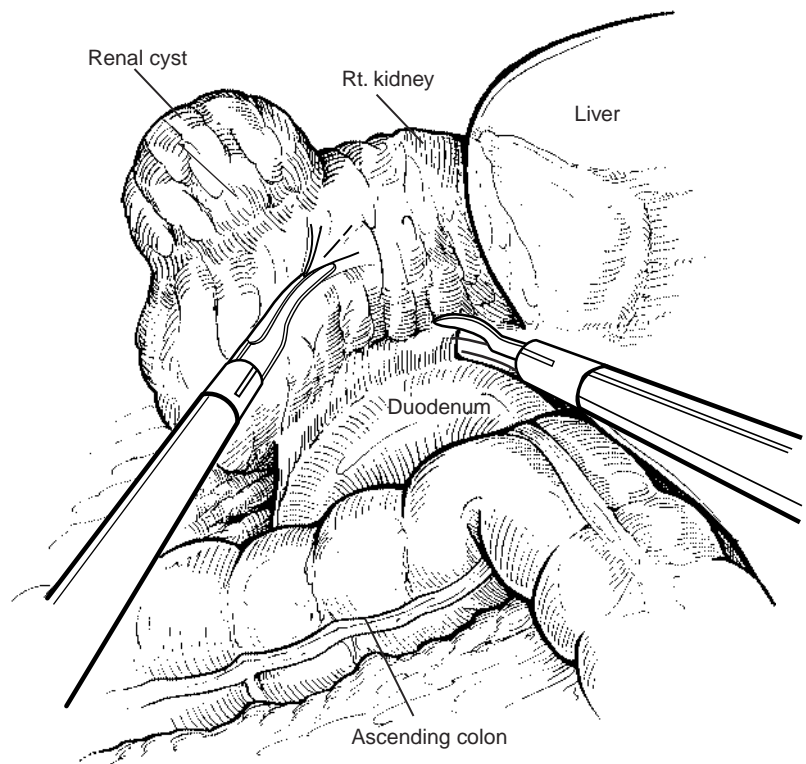


Figure 103–20. On the right side, the colon is reflected, and a Kocher maneuver may be performed to completely expose the kidney. (From Bishoff JT, Kavoussi LR [eds]: *Atlas of Laparoscopic Retroperitoneal Surgery*. Philadelphia, WB Saunders, 2000.)

phy is helpful for locating deep parenchymal renal cysts, adequate removal may be challenging, because there is a risk of injuring the collecting system and of significant bleeding (Polascik and Marshall, 1997).

Patient Preparation

All patients undergoing laparoscopic cyst biopsy should be informed that if malignancy is detected, more extensive resection may be performed including simple enucleation, partial nephrectomy, or radical nephrectomy.

If a lesion is clearly peripheral and does not involve the collecting system, a ureteral stent or catheter is not necessary. **If there is any question that a cyst may be in proximity to the collecting system, cystoscopy and placement of an open-ended ureteral catheter is performed at the time of surgery.** This is secured to a Foley catheter and prepped into the field. The ureteral catheter allows the surgeon to instill contrast material or methylene blue intraoperatively to evaluate the integrity of the collecting system after cyst excision. The external stent can be internalized at the end of the procedure, if necessary.

Patient Positioning

Patient positioning depends on the type of approach (extraperitoneal vs. transperitoneal). If cystoscopy and ureteral catheter placement are required, the patient is first placed in the supine position for flexible cystoscopy or in the dorsal lithotomy position if rigid cystoscopy is used. For patients with cysts located in the anterior portion of the

kidney, a transperitoneal approach is preferred. The patient is placed in a 45-degree modified flank position. Posterior lesions may be easier to approach through the retroperitoneum. The patient is placed in the full flank position with the lower leg flexed and the upper leg straight.

Procedure

Transperitoneal Approach

Trocar placement and renal exposure are as previously described. For right-sided dissections, caution should be exercised when dissecting the medial attachments, because the duodenum lies in close proximity. For middle pole or medial lesions, it is often necessary to mobilize the duodenum with a Kocher maneuver (Fig. 103–20). This should be done with a combination of gentle sharp and blunt dissection. The use of cautery in this area should be avoided, because an injury to the duodenum can lead to significant morbidity or death.

Gerota's fascia may need to be opened to adequately visualize the cyst. The cyst usually appears as a well-defined blue dome protruding from the surface of the kidney. If there is difficulty in identifying the location of the cyst, intraoperative ultrasonography can be performed. After visual inspection, the cyst is aspirated using a laparoscopic cyst aspiration needle, and the fluid is sent for cytopathologic analysis.

At this point, the cyst wall is excised at its junction with the parenchyma and sent for pathologic interpretation using frozen section (Fig. 103–21). If the cyst wall is too large to be easily removed through the 12-mm trocar, it should

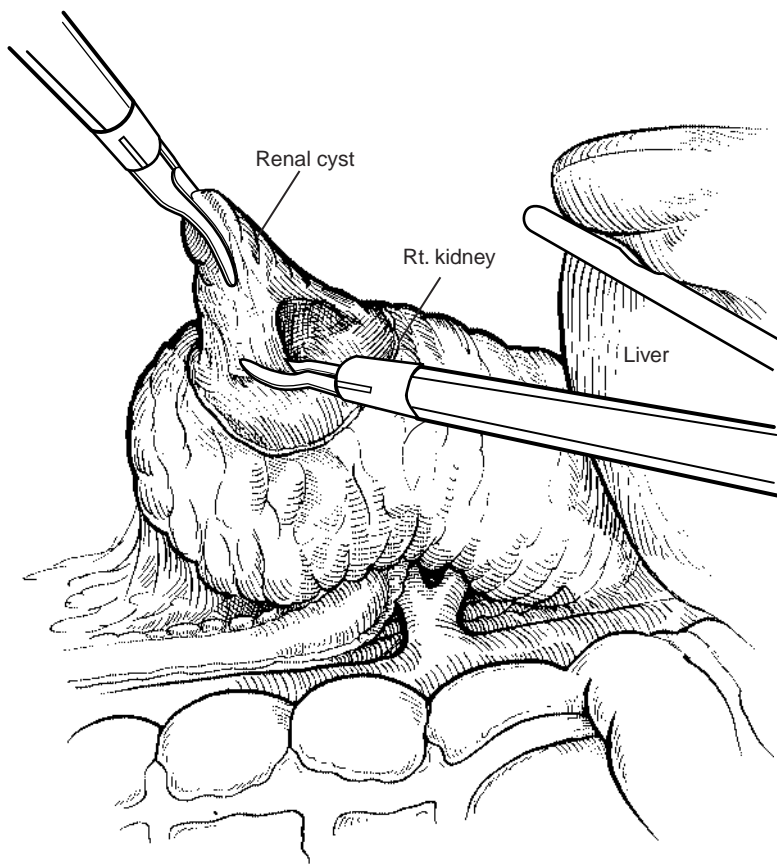


Figure 103–21. The cyst is elevated with a grasper, and scissors are used to circumferentially excise the cyst wall. The base of the cyst is carefully inspected, and biopsies are performed using the 5-mm laparoscopic biopsy forceps. Argon beam coagulation can be used at the base of the cyst as needed. (From Bishoff JT, Kavoussi LR [eds]: *Atlas of Laparoscopic Retroperitoneal Surgery*. Philadelphia, WB Saunders, 2000.)

be placed in a laparoscopic retrieval sac and removed directly through the abdominal wall trocar site. **The base of the cyst should be carefully inspected and biopsies performed using the 5-mm laparoscopic biopsy forceps. If there is no evidence of malignancy, the parenchymal surface of the cyst wall can be fulgurated with electrocautery or the argon beam coagulator. Surgical cellulose (Surgicel, Johnson & Johnson, Arlington, Texas) can be packed into the cyst base. If malignancy is noted, the patient should have a partial or radical nephrectomy, as indicated. Once the decortication is complete, careful inspection for hemostasis should be performed.**

A drain is usually not required; however, if the collecting system has been violated, it should be closed and a drain placed. This is accomplished by passing a hemostat through a small stab incision in a posterior axillary line under direct vision. A round suction drain is placed through a 10-mm trocar site and placed on one of the jaws of the hemostat (Fig. 103–22). The holes of the drain are placed in a dependent position. The colon is brought back over the kidney and attached to the sidewall to “re-retroperitonealize” the kidney and drain.

Retroperitoneal Approach

The retroperitoneal approach is used for posterior or lower pole lesions. With the patient in a full flank position, a 10-mm trocar is placed in the posterior axillary line, halfway between the iliac crest and the 12th rib. Once the trocar is in place, a pneumoretroperitoneum is established

and the anterior abdominal wall is identified with gentle dissection of the retroperitoneal fat. The peritoneum is swept medially by “hugging” the anterior abdominal wall. The second 5-mm port is placed under direct vision in the anterior axillary line as described. A third 5-mm port can be placed superior to the second port below the rib cage. Using the perinephric fat to elevate the kidney, the surgeon readily sees the lower pole and posterior surfaces. The remainder of the procedure is as described for the transperitoneal approach.

Autosomal Dominant Polycystic Kidney Disease

In cases of symptomatic ADPKD and adequate renal function, multiple cysts are marsupialized by aspirating the cyst fluid and unroofing the cyst wall with electrocautery or ultrasonic energy. It is often necessary to unroof 100 or more cysts to adequately relieve pain (Bennett et al, 1987; Elzinga et al, 1992; Elashry et al, 1996). Because of marked distortion of the anatomy, care should be taken to avoid entering the collecting system (Cherullo et al, 1999). Laparoscopic intraoperative ultrasonography can be particularly helpful in evaluating and ablating perihilar cysts, which may be in close proximity to renal vessels.

Patients with symptomatic ADPKD and renal failure are approached as described in the section “Simple Nephrectomy.” Multiple cysts are aspirated to decrease the size of the kidney, allowing access to the renal vessels for ligation

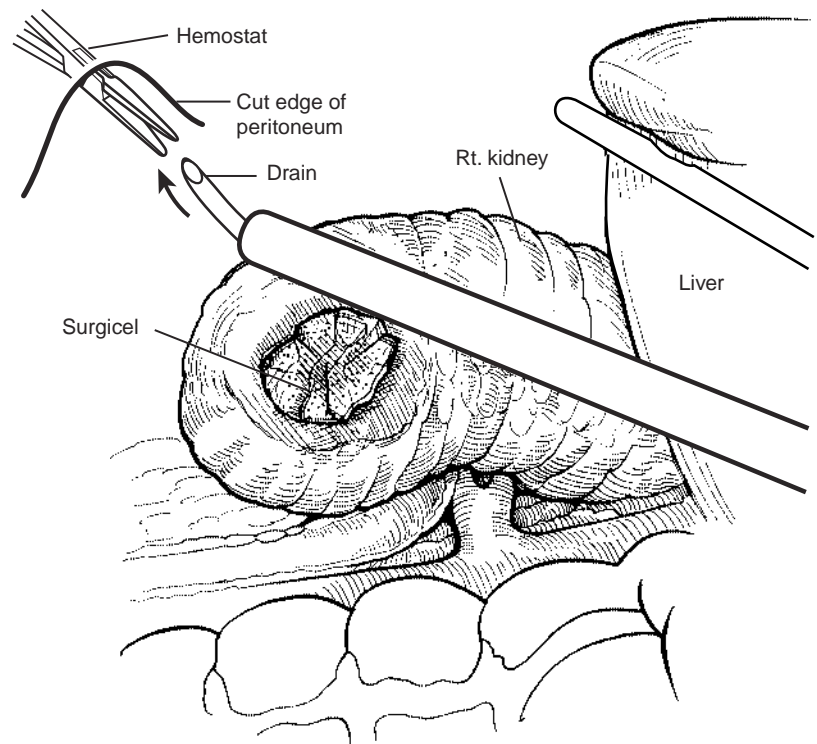


Figure 103-22. If the collecting system has been entered, it is closed and a drain placed. To insert the drain, a hemostat is passed through a small stab incision in the side and advanced into the abdominal cavity under direct vision. A 7-mm drain is placed through a trocar site and advanced toward the open hemostat using the trocar to direct the drain. The colon is brought back over the kidney and attached to the sidewall to "reperitonealize" the kidney and drain. (From Bishoff JT, Kavoussi LR [eds]: *Atlas of Laparoscopic Retroperitoneal Surgery*. Philadelphia, WB Saunders, 2000.)

and for ease of entrapment for removal or morcellation. Occasionally, the size, even after aspiration of many cysts, is too great to be manipulated into a retrieval device and requires removal through a midline incision.

Postoperative Management

Postoperative management is as with nephrectomy; however, if there is any concern regarding an injury to the collecting system, a double-pigtail stent should be left in place for up to 4 weeks. In the postoperative period, a urinoma should be in the differential diagnosis with any patient who develops a fever (> 38.5 C), persistent ileus, abdominal pain, nausea or vomiting, or an elevated white blood cell count with a left shift. CT with oral and IV contrast material can be helpful to identify a urinary leak. If a leak is detected, the bladder catheter should be reinserted, and the stent may be repositioned as indicated. Alternatively, a percutaneous nephrostomy tube can be placed. If a retroperitoneal drain was not left at the time of the procedure and a urinoma has developed, percutaneous drainage of the collection may be required.

Retroperitoneal hematomas can also occur, and the majority of these patients can be treated conservatively with observation and other supportive measures (including transfusion). Rarely, arteriography may be required to identify and treat a source of active bleeding.

Results

The laparoscopic approach to renal cystic disease has been found to be effective in decompression and pain con-

trol (Morgan and Rader, 1992; Hulbert 1992; Munch et al, 1994). In a series of nine patients with solitary symptomatic renal cysts, 100% remained pain-free at an average follow-up of 26 months (range 3 to 63 months) (Lifson et al, 1998). Similar pain-free rates were reported by Rubenstein and associates (1993) in a series of 10 patients. However, in this series, 20% of the patients (2 of 10) were found to have malignancy on cyst wall biopsy, despite a negative cytologic appearance on cyst aspiration, and subsequently underwent radical nephrectomy.

The experience with laparoscopic cyst decortication in cases of ADPKD is limited; however, they demonstrate similar results when compared with historical open series (Elzinga et al, 1993). Published series report pain-free rates ranging from 75% to 100% at 6 to 40 months of follow-up (Barry and Lowe, 1992; Chehval et al, 1995; Segura et al, 1995; Teichman et al, 1995; Elashry et al, 1996). Unfortunately, with longer follow-up, many of these patients begin having recurrent pain. Laparoscopic decortication for symptomatic ADPKD is technically feasible and less morbid than open surgery. Lifson and colleagues (1998) reported on 11 patients with ADPKD treated with laparoscopic decortication and found 88% to be pain-free at 6 months and only 25% pain-free at 3 years. In a series of 8 patients with symptomatic ADPKD, Brown and associates (1996) reported that only 50% of the patients (4 of 8) were pain-free 2 years after decortication.

Laparoscopic nephrectomy is occasionally indicated in symptomatic ADPKD patients with end-stage renal disease. Several series demonstrate the feasibility of laparoscopic removal with lower morbidity when compared with open removal. Dunn and coworkers (2000) performed 11 laparoscopic nephrectomies in nine symptomatic patients with end-stage renal disease and ADPKD. Indications for ne-

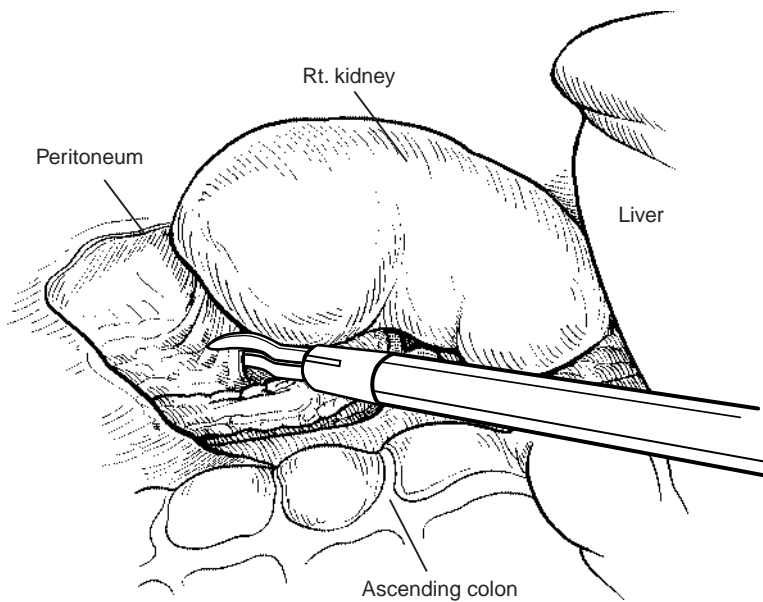


Figure 103–23. The kidney is stripped of overlying Gerota's fascia down to the kidney capsule. (From Bishoff JT, Kavoussi LR [eds]: Atlas of Laparoscopic Retroperitoneal Surgery. Philadelphia, WB Saunders, 2000.)

phrectomy included pain, hypertension, recurrent urinary tract infections, and gross hematuria. The mean operative time was 6 hours, with a mean estimated blood loss of 153 ml. The majority of kidneys were morcellated. The mean hospital stay was 3 days, and the mean time to normal activity was 5 weeks.

Kaouk and associates (2000) compared a series of 9 bilateral synchronous laparoscopic nephrectomies performed for symptomatic ADPKD to 14 open procedures performed for the same indication. None of the laparoscopic procedures required conversion to open surgery. There was no difference in operating time, specimen weight, or blood loss between the two groups. However, there was a significant difference in the length of the hospital stay (2.4 vs. 8.1 days, $P = .001$) and narcotic use (30 mg vs. 177 mg, $P = .001$) favoring the laparoscopic approach. Two patients in the laparoscopic group had a retroperitoneal hematoma that did not require surgical intervention.

NEPHROPEXY

Nephroptosis has been recognized and treated surgically since the 1800s, when nephropexy was described in Berlin by Hahn (Harrison, 1969). In one of the early urology texts, Hugh Hampton Young defined *nephroptosis* as the inferior displacement of the kidney by more than 5 cm when the patient moves from a supine to an erect position (Young and Davis, 1926). William Mayo diagnosed floating kidneys in 20% of random patients, and William Osler (1892) had recorded over 700 cases. The ptotic kidney has also been blamed for abnormality and symptoms in other organs including stomach, bowel, and pancreas. It has been estimated that over 170 innovative procedures have been described to adhere the kidney to the retroperitoneum to prevent descent while standing (Deming, 1930; Moss, 1997).

Unfortunately, nephroptosis was frequently cited as the cause of a variety of symptoms, and surgical repair was

greatly overutilized. Because repair did not afford patients relief of symptoms, this diagnosis was questioned to the point at which it disappeared from the urologic literature. However, there are patients in whom positional changes result in obstruction of the collecting system, and such patients could benefit from surgical repair. Laparoscopic nephropexy represents the latest surgical approach to treating this entity.

Indications

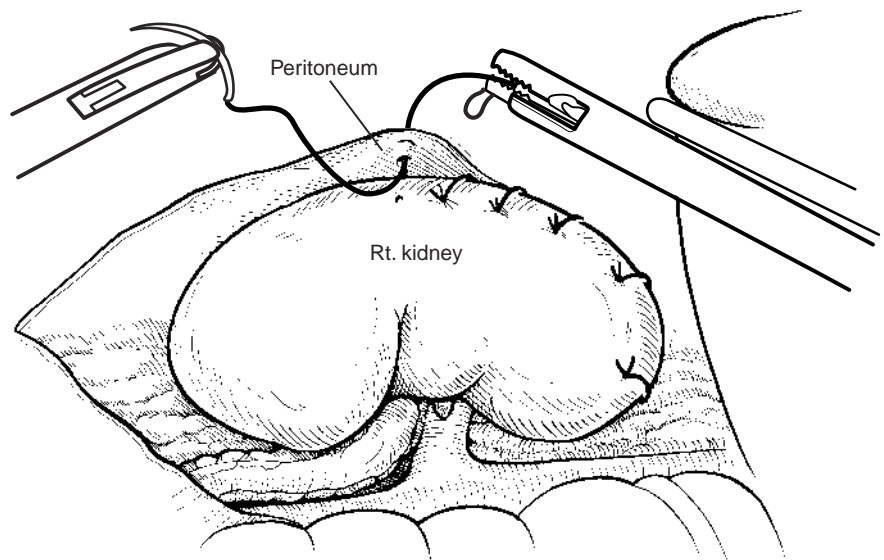
Nephroptosis is characterized by a significant downward displacement (> 5 cm) of the kidney as the patient moves from the supine to the erect position, causing pain in the abdomen or flank. The upper pole of the kidney can usually be palpated on deep inspiration. The most severe manifestation causes *Dietl's crisis* heralded by severe colicky flank pain, nausea, chills, tachycardia, oliguria, and transient hematuria or proteinuria (Irwin, 1948). The exact cause of pain is not known but is likely to be from transient renal ischemia or obstruction (Moss, 1997). **Patients who are symptomatic are generally young thin females, and pain in the erect position is the primary symptom.**

Either erect and supine IV urograms or renal scans documenting obstruction are the best diagnostic studies for nephroptosis. Descent of the symptomatic kidney by two vertebral bodies and obstruction or diminished flow to the symptomatic side should be documented before surgical repair.

Procedure

A three-port midline configuration is used and the colon is reflected medially. The peritoneal reflection and Gerota's fascia are incised over the kidney anteriorly in a T-shaped configuration. The kidney is fully mobilized by freeing the lower, lateral, posterior attachments (Fig. 103–23). Once cleared, the fascia overlying the quadratus lumborum and

Figure 103–24. Once the kidney is free of lateral and posterior attachments, multiple 2-0 sutures are placed into the capsule and the lateral edge of the fascia overlying the abdominal wall. (From Bishoff JT, Kavoussi LR [eds]: Atlas of Laparoscopic Retroperitoneal Surgery. Philadelphia, WB Saunders, 2000.)



psoas muscle is easily exposed. **The patient is placed in an extreme head-down position to assist with kidney positioning during suturing.** Starting at the upper pole, a series of interrupted sutures are placed laparoscopically between the lateral edge of the capsule of the kidney and the fascia overlying the quadratus lumborum (Fig. 103–24). Four to six nonabsorbable 2-0 sutures are placed in the upper to lower lateral border of the kidney. The subhepatic parietal peritoneum may also be sutured to the anterior portion of the renal capsule to provide additional support for the kidney if feasible. The pneumoperitoneum is lowered to 5 mm Hg, and careful inspection for any bleeding along the suture lines is performed.

Symptomatic evaluation, along with erect and supine radiographic studies, is performed 6 to 8 weeks after surgery to evaluate the efficacy of the repair.

Results

McDougall and associates (2000) reported a series of laparoscopic nephropexy in 14 women with right flank pain and documented nephroptosis. The average operating room time was 4 hours, and the mean hospital stay was 2.6 days. At a mean follow-up of 3.3 years, patients reported an average of 80% improvement in pain (range 56% to 100% improvement).

Fornara and associates (1997) reported a series of 23 patients (22 women and 1 man) who underwent laparoscopic nephropexy. The mean operative time was 60 minutes, and they reported no complications or conversions to an open procedure. A pain analogue scale was used to measure changes in symptoms before and after surgery. They performed IV pyelography and renal scans at 6 weeks after surgery. Split renal function while erect improved from 38% preoperatively to 47% postoperatively ($P = .03$). At a mean follow-up of 13 months (range 2 to 37 months), pain intensity had improved in 21 patients. The laparoscopic group was retrospectively compared with a series of 12 patients treated with open nephropexy. Follow-up in the open group at a mean 7.6 years showed four

patients pain-free, five with occasionally pain, and three without any resolution of symptoms.

Nephropexy is rarely indicated today. Patients with nephroptosis are often asymptomatic, and many that are symptomatic do not require surgery for this condition. Patients who are markedly symptomatic and have documented changes in the kidney position from the supine to the erect position may benefit from the effective and less morbid treatment of laparoscopic nephropexy.

PYELOLITHOTOMY

The treatment of renal stones has gone through dramatic changes with the advent of extracorporeal shock wave lithotripsy (ESWL), percutaneous nephrolithotomy, and ureteroscopic laser lithotripsy. These new techniques have almost eliminated the need for pyelolithotomy to remove renal stones; however, there are some patients who benefit from laparoscopic pyelolithotomy. **Individuals to be considered for this approach include those in whom ESWL has failed, percutaneous or ureteroscopic procedures, patients with unusual anatomy such as the pelvic kidney, and patients with stones resistant to fragmentation such as those of cystine composition.** Successful laparoscopic transperitoneal pyelolithotomy has been reported in ectopic kidneys with stones from 2 to 4 cm (Chang and Dretler, 1996; Harmon et al, 1996; Hoening et al, 1997).

When stones develop in pelvic or ectopic kidneys, treatment may be challenging. ESWL is acceptable for initial treatment but may not be successful because of the stones' composition or position or the anatomy of the renal collecting system. Percutaneous techniques risk damage to anomalous vasculature with subsequent bleeding. To avoid damage to vessels in ectopic kidneys, several authors have used laparoscopic visualization to direct percutaneous access (Eshghi et al, 1985; Toth et al, 1993).

In 1994, Gaur and colleagues reported successfully removing five of eight stones utilizing retroperitoneal laparoscopic pyelolithotomy. In two patients, the kidney was not accessed because of failure in retroperitoneal dilatation

techniques. Once access to the kidney was obtained, the stones were successfully removed in five of six cases. In one case, attempts to palpate the stone in the renal pelvis before pyelotomy dislodged the stone into an upper pole calyx requiring open conversion for removal.

CALYCEAL DIVERTICULECTOMY

Calyceal diverticula are congenital transitional cell-lined cavities that communicate with the collecting system through narrow infundibula. Although the diverticula do not produce urine, they passively fill from the collecting system. Because the narrow infundibula causes urine to drain slower than in other areas in the collecting system, they are predisposed to stone formation from urinary stasis. It is estimated that 9% to 35% form stones (Middleton and Pfister, 1974; Timmons et al, 1975; Donnellan et al, 1999). The most common symptoms include pain in the back or flank, infection, and hematuria.

The management of calyceal diverticula has always been challenging. The classic management was by open surgery. Partial nephrectomy and open marsupialization with fulguration of the diverticulum and even total nephrectomy have been used in the past (Devine et al, 1969; Williams et al, 1969; Wulfsohn, 1980). Advances in less invasive equipment and techniques have changed the treatment of these difficult cases.

The ideal means of treating symptomatic calyceal diverticula include removal of the stones and widening of the infundibulum to prevent urine stasis or ablation of the diverticular cavity. Percutaneous treatment is most often used for treatment in symptomatic cases (Donnellan et al, 1999). ESWL and ureteroscopy have also been applied, but anatomic factors can result in a lower rate of achieving stone clearance (Jones et al, 1991; Pang et al, 1992; Stream et al, 1992;). Recurrence of symptoms and stones can occur if the diverticulum has not been ablated.

Indications

Large peripheral diverticula and those located medially near the renal hilum may best be treated using laparoscopic techniques. A laparoscopic approach allows evacuation of the stone fragments, careful inspection, and fulguration of the cavity using argon beam or standard monopolar coagulation. Additionally, perirenal fat can be inserted into the cavity to decrease the chance for recurrence.

Procedure

As with the treatment of renal cysts, the location of the diverticulum helps dictate a transabdominal or retroperitoneal approach. Gerota's fascia is opened and perirenal fat cleared from the surface of the kidney. **The location of the diverticulum is usually readily identified by the presence of dense adhesions from the surface of the kidney to surrounding fat and a "dimpling" on the surface of the kidney. Intraoperative fluoroscopy or ultrasonogra-**

phy can also be used to confirm the location of deeper renal cysts. Once located, the thin parenchyma over the cavity is cauterized and opened. Spoon graspers are useful for removing stones intact. Milk of calcium stones and many small stone fragments can be encountered, despite the appearance of a solitary dense stone on conventional radiographs. With the use of graspers and scissors, the diverticulum opening is enlarged to the point of encountering normal renal parenchyma and is unroofed. Argon beam coagulation or monopolar cautery is used to fulgurate the lining of the cavity to prevent recurrence. Methylene blue can be given intravenously, and careful inspection allows detection of blue urine in the cavity, indicating communication with the collecting system. The collecting system can be closed using laparoscopic suturing techniques and perirenal fat inserted into the cavity. Stenting and drainage are usually performed.

Results

Several authors have reported successful laparoscopic treatment of calyceal diverticula (Gluckman et al, 1993, Ruckle and Segura, 1994, Harewood et al, 1996, Donnellan et al, 1999). Patients benefited from the advantages of a laparoscopic approach; however, most of these series were small, with limited follow-up.

LAPAROSCOPY FOR RENAL MALIGNANCY

The use of laparoscopy in the treatment of renal malignancies has generated a great deal of controversy based on fear of inadequate cancer control. Early laparoscopic experiences in the surgical and gynecologic literature have raised concerns regarding the risk of port site seeding, inadequate surgical margins, and inaccurate staging due to morcellation. Experience has borne out that laparoscopic removal in experienced hands provides equivalent cancer control when compared with traditional open approaches.

Port site recurrence after laparoscopic procedures in cancer patients has been described in the general surgery, gynecology, and urology literature. In a broad survey of over 1050 European general surgery programs, port site recurrence occurred in 17% of laparoscopic cholecystectomies for incidental gallbladder carcinoma and in 4.6% of cases of colorectal cancer (Paolucci et al, 1999). Studies have demonstrated that tumor cells may be deposited at the port site during laparoscopy either directly from contaminated instruments or indirectly by way of insufflation gas (Neuhaus et al, 1998; Schaeff et al, 1998; Whelan and Lee, 1999).

In the urologic literature, there have been occasional reports of laparoscopic port site seeding of transitional cell, prostate, and renal cell carcinomas. Bangma and coworkers (1995) reported on the first patient with port site seeding after laparoscopic pelvic lymph node dissection (LPLND) for prostate cancer. In contrast, Cadeddu and associates (1996) found no cases of port site seeding after 372 cases of LPLND. A review of a subset of 40 patients with positive pelvic lymph nodes for prostate cancer (at the time

of LPLND) revealed no instance of port site seeding up to 3 years after surgery. Furthermore, there was no acceleration in the natural history of the disease after laparoscopic pelvic lymph node procedures (Kavoussi et al, 1993).

In the laparoscopic staging and treatment of transitional cell carcinoma, there have been five reports of port site seeding (Stolla et al, 1994; Anderson and Steven, 1995, Ahmed et al, 1998; Elbahnasy et al, 1998; Otani et al, 1999). In three instances, port site recurrence developed after laparoscopic staging with a biopsy or LPLND of a primary bladder tumor. In one of two cases related to nephrectomy, seeding developed in a patient with a tuberculous atrophic kidney containing unsuspected transitional cell carcinoma.

To date, there have been two reports of port site seeding after laparoscopic radical nephrectomy for renal cell carcinoma. In a series of 94 laparoscopic radical nephrectomies with specimen morcellation, one patient with T3, N0, M0 disease suffered a solitary recurrence at one trocar site, 25 months after radical nephrectomy (Fentie et al, 2000). In the second case, a patient with a T1, N0, M0 renal cell carcinoma (Furhman grade II) underwent transperitoneal radical laparoscopic nephrectomy with morcellation of the specimen. Five months later, the patient developed disseminated metastatic renal cell carcinoma, carcinomatosis, and recurrence at all the trocar sites (Fugita et al, 2000).

When the reported cases are evaluated in terms of port site seeding, several common elements emerge. Multiple cases involve instances in which malignancy was unexpected or was being determined with a biopsy. Thus, basic principles of cancer surgery were violated. Moreover, in many cases, metastatic disease or malignant ascites was already present. The majority of cases involved removal of tissue either directly through a trocar site or through a small incision without the protection of an entrapment sac.

In order to prevent port site seeding and tumor spillage, one must take several steps. First, the basic principles of cancer surgery developed over the years must be followed. Direct handling of the tissue must be minimized and all attempts made to prevent violation of the tumor. Attempts should be made to perform a wide en bloc dissection to obtain an adequate surgical margin. All potentially cancerous tissue should be entrapped in an impermeable sack and the field draped before morcellation or extraction (Urban et al, 1993). All possible contaminated instruments should be removed from the operative field. Ascitic fluid suspicious for malignancy should be sent for cytologic examination.

Morcellation of specimens for extraction has raised concerns about accurate pathologic staging. **CT has been proved to be an effective tool for planning surgery and predicting pathologic findings. The overall accuracy of CT in staging renal cell carcinoma ranges from 72% to 90%** (Johnson et al, 1987; London et al, 1989; Parks and Kelley, 1994; Zagoria et al, 1995). **In a review of 172 renal tumors treated with open radical nephrectomy, Shalhav and coworkers (1998) correlated the preoperative CT-based clinical stage with the final pathologic tumor stage. They found one patient (0.6%) to be understaged and seven (4%) overstaged by preoperative CT. They concluded that clinical CT staging of low-stage renal tumors is reliable and tends to overstage**

rather than understage renal tumors. Currently, if a patient with clinically localized renal cell carcinoma is found to have microscopically advanced disease, there is no effective adjunct therapy. Thus, morcellation does not alter subsequent follow-up or treatment. The long-term follow up in laparoscopic series in which kidneys are morcellated compared with open radical nephrectomy shows equivalent cancer-free survival (Chan et al, 2000; Ono et al, 2000). When pathologic staging is required, the specimen may be removed intact through a low midline or Pfannenstiel incision.

RADICAL NEPHRECTOMY

Radical nephrectomy for patients with clinically localized renal cell carcinoma provides the best opportunity for cure. However, the pain and morbidity associated with an open flank incision can be significant. The laparoscopic approach to renal cell carcinoma has evolved into a safe and effective minimally invasive alternative to open surgery. The perioperative benefits of the procedure are well established, and as long term follow-up matures, the disease-free and cancer-specific survival rates for laparoscopic radical nephrectomy are comparable with those of open surgery (Table 103-7).

Indications and Contraindications

Laparoscopic radical nephrectomy has been applied to patients with advanced stages of renal cell carcinoma (Walther et al, 1999). **Contraindications to laparoscopic radical nephrectomy include tumors with renal vein or vena cava thrombi.** To date, a reliable method to perform a laparoscopic thrombectomy does not exist. Patients with a prior history of ipsilateral renal surgery, perinephric inflammation, or extensive intra-abdominal surgery may still be candidates for laparoscopic surgery based on the experience of the surgeon and an informed patient who understands that it may be necessary to convert to open surgery. Locally advanced disease may also require open conversion.

Preoperative Evaluation

The preoperative evaluation of the patient with a suspected renal malignancy is the same whether an open or a laparoscopic approach is planned. A complete metastatic evaluation is necessary and includes a chest radiograph or CT and abdominal CT scans. A bone scan is obtained in patients with elevated serum calcium or alkaline phosphatase levels and in those with symptomatic bone pain. If there is a question of renal vein tumor thrombus, then an appropriate study (MRI, venography, sonography, or three-dimensional CT) to preoperatively evaluate the vein is required.

Contralateral renal function is assessed before radical nephrectomy by measuring serum creatinine levels and evaluating the kidney appearance on contrast-enhanced CT. In equivocal cases, a functional renal scan and 24-hour

Table 103–7. LAPAROSCOPIC RADICAL NEPHRECTOMY SERIES (MEAN VALUES PRESENTED FOR EACH CATEGORY)

Author	Approach	Indication	OR Time (Min)	LOH (Days)	EBL (ml)	Conversion (%)	Complications (%)	Morcelation (%)	Intact (%)	Follow-up (mo)	Local Recurrence (%)	Metastatic Disease (%)
McDougall et al, 1996	Transperitoneal N 17	T1–T2	414	4	105	6	18	29	71	14	0	0
Cadeddu et al, 1998	Transperitoneal N 139	T1, T2	na	na	na	4	10	90	10	19	1	3
	Retroperitoneal N 18											
Abbou et al, 1999	Retroperitoneal N 29	T1	145	5	100	0	8	0	100		3	0
Ono et al, 1999	Transperitoneal N 34	T1, T2	300	11	225	2				60	0	3
	Retroperitoneal N 15											
Barrett and Fentie, 1999	Transperitoneal N 94	T1–T4	173	4.6		10	9	89	11	36	4	2
Gill et al, 2000	Retroperitoneal N 53	T1, T2	180	2	128	4	17	0	100	13	0	4
Jeschke et al, 2000	Transperitoneal N 51	T1, T2	125	7		0	4	0	100	8	0	0
Janetschek et al, 2000	Transperitoneal N 100	T1, T2	137	7	168	0	10	0	100	14	0	0
Dunn et al, 2000	Transperitoneal N 55	T1, T2, T3	330	3.4	172	1	3*	65	35	25	0	8
	Retroperitoneal N 6											
Chan et al, 2001	Transperitoneal N 67	T1, T2	256	3.8	289	1	15	60	40	21	0	3

*Major complications

EBL, estimated blood loss; LOH, length of hospitalization; na, not applicable; OR, operating room.

urinary creatinine clearance studies can be obtained. The presence of renal insufficiency should prompt the surgeon to consider partial nephrectomy.

Positioning and Trocar Placement

Patient positioning and trocar placement are similar to those described for the simple nephrectomy (see Fig. 103–3). Three ports are generally sufficient to complete the procedure, although a fourth trocar may be necessary for organ entrapment and liver retraction during right-sided nephrectomy.

Procedure

Reflection of the Colon

The colon is reflected to provide adequate visualization of the anterior surface of Gerota's fascia. On the right, the duodenum is mobilized medially, using the Kocher maneuver, until the vena cava is clearly visualized.

Dissection of the Ureter

The midureter is located in the retroperitoneal fat medial to the psoas muscle. During proximal mobilization, the gonadal vein is usually first encountered and should be swept medially. The ureter is located just posterior to this

structure (Fig. 103–25). Once located, the ureter is elevated, revealing the psoas muscle and traced proximally to identify the renal hilum.

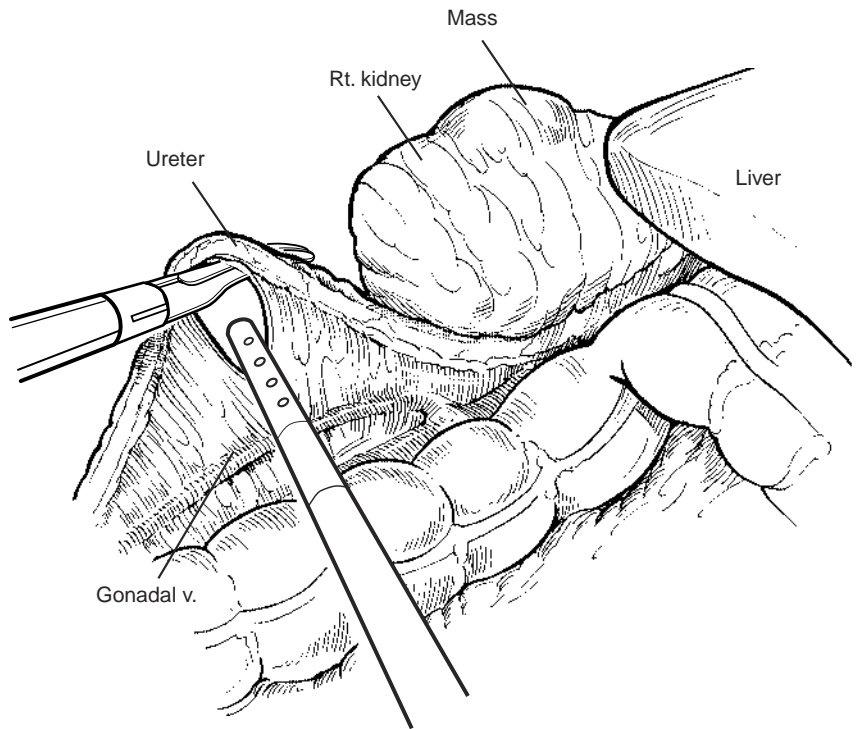
Mobilization of the Lower Pole

As opposed to a simple nephrectomy, the radical nephrectomy preserves Gerota's fascia so that the renal parenchyma and mass are not visualized during this operation. Once the ureter is mobilized up to the ureteropelvic junction, forceps are inserted beneath Gerota's fascia and lower pole along the psoas fascia. The specimen is lifted superolaterally, and, with the use of the suction-irrigator and electro-surgical scissors, the inferior and posterior side-wall attachments are divided. The inferior cone of Gerota's fascia lateral to the ureter is also divided. To facilitate this dissection and assist with lateral specimen retraction during the hilar dissection, the fourth port may be necessary as outlined earlier.

Securing the Renal Blood Vessels

During right-sided radical nephrectomies, retraction of the liver to improve visualization of the renal hilum and upper pole can be accomplished by passing a 3- or 5-mm instrument through a fourth trocar placed below the ribs in the anterior axillary line. The renal artery and vein are individually dissected and divided. The surgeon places the renal hilum on gentle tension by lifting the lower pole

Figure 103–25. The ureter and gonadal vein are elevated with a grasper and mobilized cephalad. As the cephalad dissection approaches the renal hilum, the gonadal vein crosses anterior to the ureter. (From Bishoff JT, Kavoussi LR [eds]: *Atlas of Laparoscopic Retroperitoneal Surgery*. Philadelphia, WB Saunders, 2000.)



laterally. With the use of the electro-surgical scissors and the suction-irrigator, the hilum is identified by moving cephalad along the medial aspect of the ureter and renal pelvis. The renal vein is usually identified first and is dissected circumferentially. Lumbar veins must be identified and divided between a pair of double clips. After the renal vein is dissected, the renal artery is identified and transected with the GIA stapler (Fig. 103–26). For left-sided tumors, the GIA is placed proximal to the adrenal vein if the adrenal gland is to be taken with the specimen. If the gland is to be left, the GIA is positioned distal to the adrenal vein. Extended lymphadenectomy can be readily performed once the vessels are identified and dissected circumferentially.

Dissection of the Upper Pole

The decision whether to remove the ipsilateral adrenal with the specimen determines the superior margin of dissection. If the adrenal is not removed, upper and lateral attachments to Gerota's fascia are incised utilizing the electrocautery scissors. Care must be taken to avoid injury to the diaphragm at this point. In some cases, it may be helpful to transect the ureter and rotate the lower pole of the kidney over the liver (right) or spleen (left) to incise upper pole posterior attachments.

If the adrenal is to be removed with the specimen, control and division of the adrenal vein is imperative. On the right side, dissection cephalad along the vena cava identifies the adrenal vein. Once it is divided, the superior, medial, and posterior attachments of the adrenal are mobilized (Fig. 103–27). On the left side, the adrenal vein is left in continuity with the specimen by transection of the renal vein proximal to the take-off of the adrenal branch.

Specimen Entrapment and Extraction

Intra-abdominal entrapment of the excised specimen is performed to facilitate removal. If it is to be removed intact through an incision, an Endocatch device is recommended. It consists of a plastic sack attached to a self-opening, flexible metal ring. The primary advantage of a self-opening bag is that the specimen can be easily manipulated into the opening of the bag with a single grasper.

The retrieval device is 15 mm and thus needs to be placed through one of the 10-mm trocar sites after the trocar has been removed (Fig. 103–28). Once the specimen is placed into the sack, the opening is withdrawn through the trocar site. Using electrocautery, the trocar site is enlarged to allow extraction of the specimen, and the specimen and sack are protected by the surgeon's finger positioned through the trocar site alongside the specimen (Fig. 103–29). Alternatively, the kidney can be removed through a Pfannenstiel incision.

If the specimen is to be morcellated, a LapSac (Cook Urological, Inc., Spencer, Indiana) fabricated from a double layer of plastic and nondistensible nylon is used. This sac has been shown to be impermeable to bacteria and tumor cells even after its use for morcellation (Urban et al, 1993). The LapSac is introduced and held open with several graspers (Fig. 103–30). Once the specimen is inside the entrapment sack, the drawstring is grasped, tightened, and withdrawn into the 10-mm umbilical port. The sack is pulled tightly against the abdomen and morcellation initiated. The pneumoperitoneum should be preserved throughout the morcellation process so that the intra-abdominal portion of the sack can be monitored laparoscopically for possible perforation. Surgical towels are placed around the sack, and the entire surgical field is

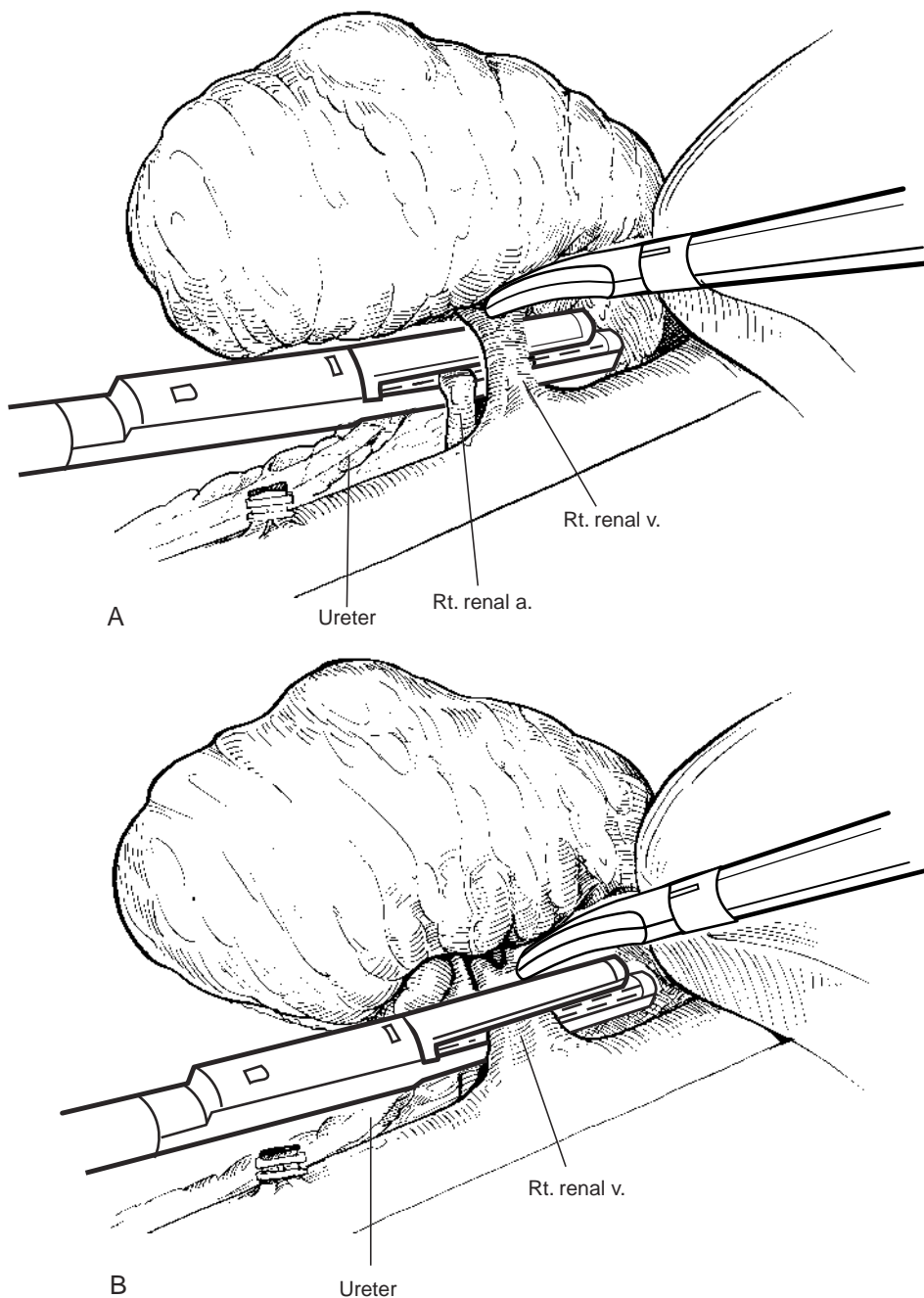


Figure 103-26. *A*, After mobilization of the lower pole and posterior attachments, the renal hilum is exposed. The vein is displaced to expose the artery, and a plane is dissected to allow the introduction of the vascular GIA stapler. *B*, The renal vein is also divided with an endoscopic vascular stapler after the artery or arteries have been secured. (*A* and *B*, From Bishoff JT, Kavoussi LR [eds]: *Atlas of Laparoscopic Retroperitoneal Surgery*. Philadelphia, WB Saunders, 2000.)

covered to prevent port site contamination with any spillage of the morcellated specimen (Fig. 103-31).

Results

The cancer-free survival results seen in radical open nephrectomy represent the standard that must be met for laparoscopic radical nephrectomy to be considered equivalent in the treatment of renal cancer. Ono and associates (1999, 2000) reported results from a series of 125 patients with a mean follow-up of 28 months (range 1 to 87 months). One patient (0.8%) died of surgical complications in the immediate postoperative period, and a second patient died of unrelated disease 42

months after surgery. In the remaining 123 patients, there were no local recurrences and no port site seeding. Three patients developed metastatic disease at 3, 19, and 61 months. Cancer-free survival was 99% during the first year, 97% at 5 years, and 83% at 7 years. None of the patients with tumors greater than 5 cm developed metastatic disease during the follow-up period.

Similar results were described by Fentie and colleagues in a series of 57 patients with T1 to T4 renal cell tumors followed for a mean 33.4 months (range 14 to 70 months). All patients were treated laparoscopically, and in each case the kidney morcellated. Three patients developed metastasis. One patient with a pathologic T3, N0, M0, grade III/IV tumor developed a re-

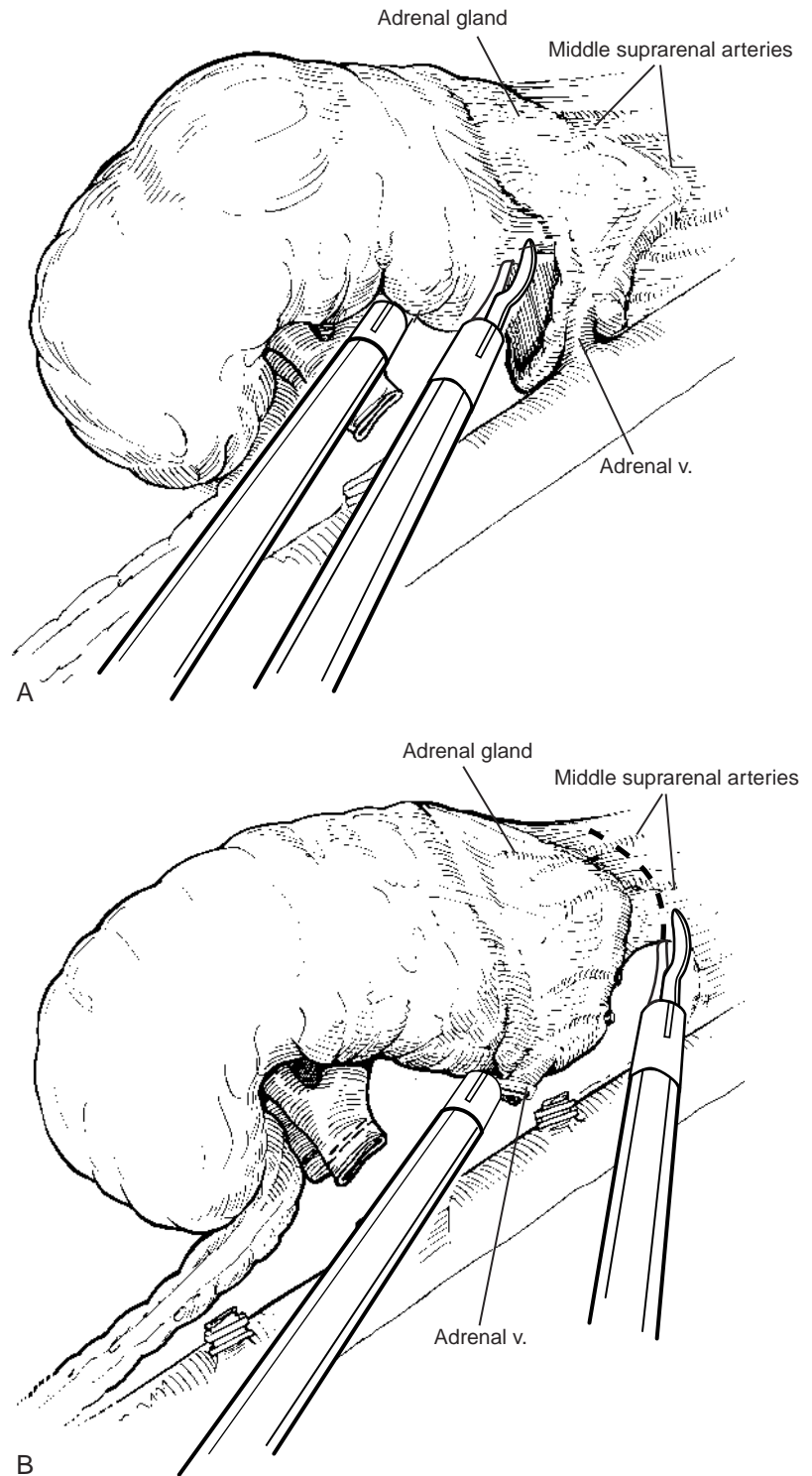


Figure 103–27. A, Adrenal-sparing right radical nephrectomy. Sharp cautery dissection is employed to release all adrenocolic attachments. Inferior retraction of the specimen facilitates exposure of this surgical plane. B, Inclusion of the adrenal with right radical nephrectomy. (A and B, From Bishoff JT, Kavoussi LR [eds]: Atlas of Laparoscopic Retroperitoneal Surgery. Philadelphia, WB Saunders, 19xx.)

currence in the renal fossa and chest metastasis 14 months after surgery. A second patient with a pathologic T2, N0, M0 grade II/IV tumor developed metastasis to the bone 20 months after radical nephrectomy. Finally, a patient with a pathologic T3, N0, M0 grade IV/IV tumor developed a solitary port site recurrence more than 2 years after nephrectomy (Barrett and Fentie, 1998; Fentie et al, 2000).

Dunn and coworkers (2000) reported an 8% renal

cell carcinoma recurrence rate in 61 patients undergoing laparoscopic radical nephrectomy. The mean follow-up in this series was 25 months (range 3 to 73 months). The clinical stage was T2, N0, M0 in two of three cases with cancer recurrence and T1, N0, M0 in one case. In all three cases, the tumors were Fuhrman's grade III/IV.

Cadeddu and colleagues (1999) presented a multi-institutional review of 157 patients with clinically localized path-

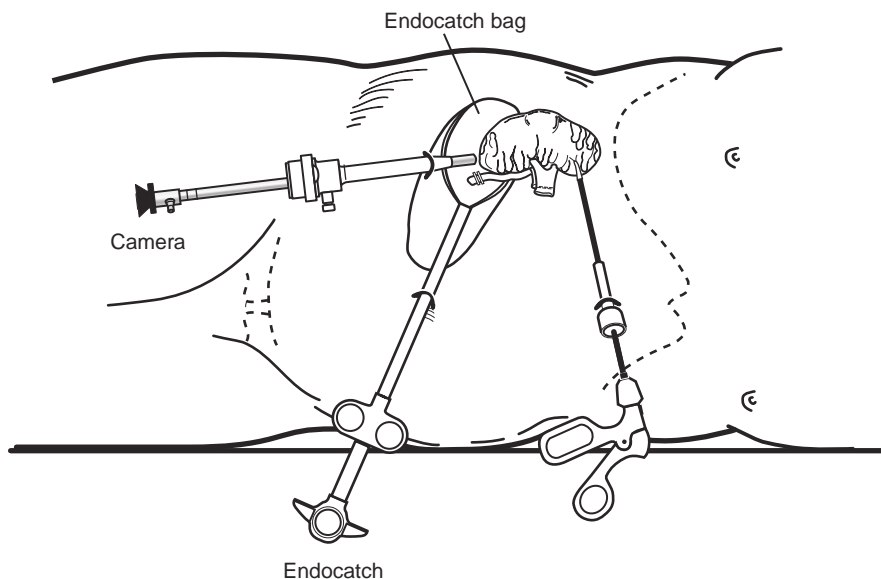


Figure 103-28. Placement of a specimen into an opened Endocatch device placed through an umbilical trocar site. Note that the camera is positioned in the lateral port and the specimen is maneuvered through the upper midline trocar. (From Bishoff JT, Kavoussi LR [eds]: Atlas of Laparoscopic Retroperitoneal Surgery. Philadelphia, WB Saunders, 2000.)

ologically confirmed renal cell carcinoma treated laparoscopically. They reported an actuarial 5-year disease-free survival of 91% and no cancer-specific mortality. There were no local disease recurrences or port site seedings. In a series of 100 laparoscopic radical nephrectomies followed for a mean of 14 months, Janetschek and colleagues (2000) also found no local recurrences and no port site seedings.

Chan and associates (2001) reported their experience comparing 67 laparoscopic nephrectomies with 54 patients undergoing open removal. All patients were clinical stage

cT1 to cT2, N0, M0. In terms of patient age, tumor size, and estimated blood loss, there were no differences between the two procedures. The patients in the laparoscopic group, however, did consistently have a shorter period of hospitalization. The mean operating time was 193 minutes in the open group, which was faster than in the laparoscopic group (256 minutes). A significant operating time difference between the first 34 and last 33 laparoscopic radical nephrectomies existed, reinforcing the notion of the learning curve.

The calculated disease-free rates for laparoscopic and open radical nephrectomy were 95% and 86%, respectively, at 5 years, and the actuarial survival rates for laparoscopic and open radical nephrectomy were 86% and 75%, respectively, at 5 years. These differences were not significant, and no laparoscopic trocar site implantation was identified. One operative conversion (1.5%) was required in the laparoscopic group. **Complications occurred in 10 patients (15%) in the laparoscopic group and 8 (15%) in the open group. Six laparoscopic patients required blood transfusions (8%) compared with 11 in the open group.**

Gill and associates (2000) compared a series of 53 laparoscopic radical nephrectomies to 34 open radical nephrectomies. There were no differences in body mass index, age, American Society of Anesthesiologists status, tumor size, specimen weight, or surgical time between the two groups. In the 53 laparoscopic radical nephrectomies for tumors with a mean size of 4.6 cm (range 2 to 12 cm), the mean specimen weight was 484 g. All specimens were removed intact. Minor complications occurred in eight patients (17%), and major complications requiring conversion to open surgery occurred in two patients (4%). The laparoscopic approach was found to have less blood loss ($P = .001$), a shorter hospital stay ($P = .001$), lower analgesic requirements ($P = .001$), and shorter convalescence ($P = .005$) compared with open radical nephrectomy. Complications were seen in 13% of the laparoscopic patients and in 24% of the open surgical candidates. Similar results have been reported by other investigators comparing open and

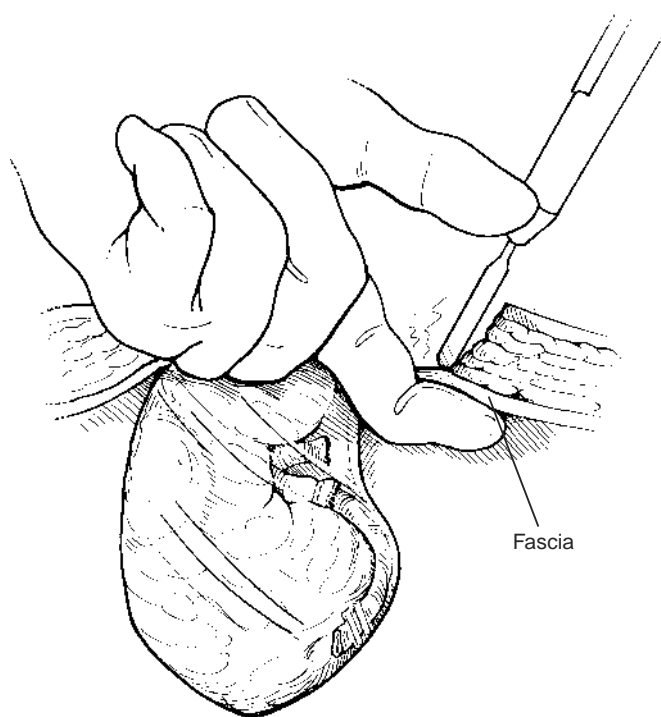
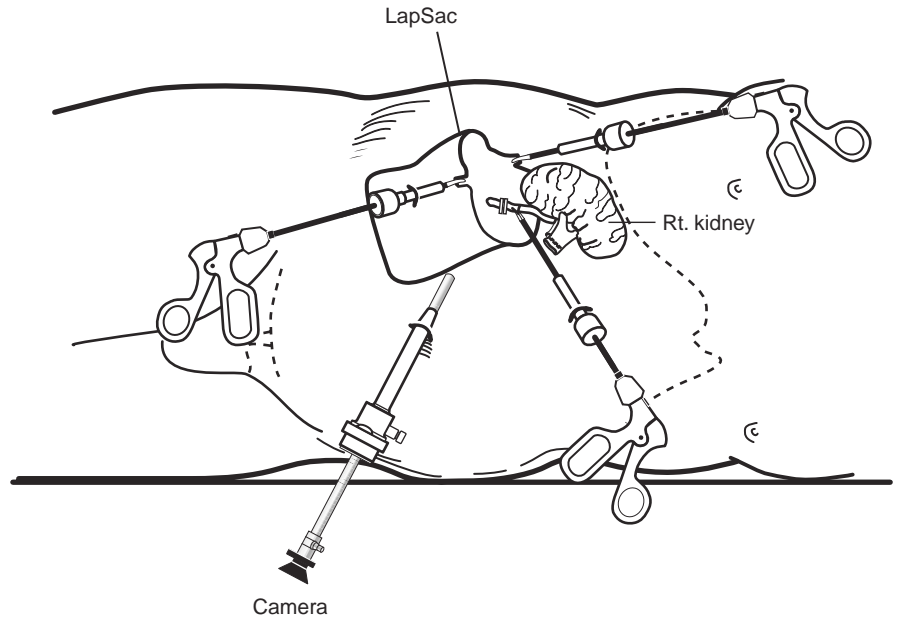


Figure 103-29. For removal of the intact specimen, a 4- to 6-cm incision is made including one of the trocar sites. The surgeon's finger protects the specimen and underlying structures. (From Bishoff JT, Kavoussi LR [eds]: Atlas of Laparoscopic Retroperitoneal Surgery. Philadelphia, WB Saunders, 2000.)

Figure 103–30. For morcellation, the LapSac (Cook Urological, Inc., Spencer, Indiana) entrapment sack is introduced through the lateral 10-mm trocar site. After the entrapment sack is released within the abdomen, the 10-mm port is replaced and the sack unfurled. To place the specimen within the sack, a lateral 5- or 3-mm port may be necessary to assist with holding the bag open. Once the specimen is within the Lapsac, the bag is cinched closed and withdrawn through the 10-mm lateral trocar. (From Bishoff JT, Kavoussi LR [eds]: Atlas of Laparoscopic Retroperitoneal Surgery. Philadelphia, WB Saunders, 2000.)



laparoscopic radical nephrectomy (Kerbl et al, 1994; McDougall et al, 1996; Clayman et al, 1997)

Conclusion

Laparoscopic radical nephrectomy is in its infancy compared with standard open radical nephrectomy. Early reports have clearly shown it to be less morbid than open surgery. The reported 5-year survival of patients indicates that the cancer-free survival is comparable to that seen after open radical nephrectomy. Longer follow-up with larger numbers of patients will help confirm the efficacy of laparoscopy in treating organ-confined renal cell carcinoma.

PARTIAL NEPHRECTOMY

Partial nephrectomy was initially reserved for patients at high risk for developing renal failure after kidney surgery to treat renal cancer. **Several series have shown partial open nephrectomy to be equivalent to open radical nephrectomy in terms of long-term cancer-free survival with unilateral renal involvement, unifocal disease, and a tumor size less than 4 cm.** Fergnany and coworkers (2000) report a **10-year cancer-specific survival of 100% in this subset of patients.** Lee and associates (2000) have reported a series of 79 patients treated with open partial nephrectomy for tumors less than 4 cm compared with 183 patients with the same stage of renal cancers treated with open radical nephrectomy. They found no local recurrence and no significant difference between the two groups in disease-specific, disease-free, or overall survival. **In a matched comparison of 1566 open radical nephrectomies and 164 nephron-sparing procedures, Lau and colleagues (2000) reported no overall or cause-specific survival advantage at 5, 10, and 15 years for the radical nephrectomy group. Additionally, they found comparable early complications and similar rates of local re-**

currence and distant metastasis. The only difference discovered was an increased risk of developing renal insufficiency after open radical nephrectomy ($P = .002$). The widespread use of modern imaging techniques has resulted in a 32% decrease in the mean tumor size since

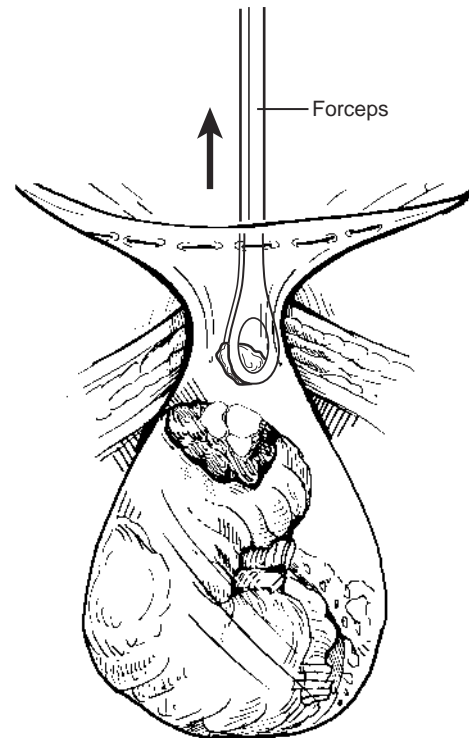


Figure 103–31. The entrapment sack is pulled tightly up against the abdominal wall with two hands. After the site is carefully draped, manual morcellation with ring forceps or a Kelly clamp can be used, and the entrapment sack is removed once the remaining specimen fragments are small enough to be extracted through the trocar site. (From Bishoff JT, Kavoussi LR [eds]: Atlas of Laparoscopic Retroperitoneal Surgery. Philadelphia, WB Saunders, 2000.)

Table 103–8. LAPAROSCOPIC NEPHRON-SPARING SURGERY

Author	N	Size (cm)	OR Time (Min)	EBL (ml)	Lesion	Margins	LOH (days)	Follow-up (Mo)	Complications
Janetschek et al, 1998	7	1–2	231 (180–300)	311 (190–800)	Renal cell 5 Complex cyst 5	7/7 neg	4.5 (3–6)	18 (7–35) No recurrence	Pneumothorax
Abbou et al, 2000	53	1–5	191 (90–320)	725 (90–320)	Renal cell 35 Benign 15	N/A	5.4	36 No recurrence	Covert open 3 Delayed bleed 1 SBO 1
Harmon et al, 2000	15	1–3	170 (105–240)	368 (75–100)	Lymphoma 1 Renal cell 12 Oncocytoma 3	15/15/neg	2.6 (2–3)	8 (1–18) No recurrence	Trocar site Infection

EBL, estimated blood loss; LOH, length of hospitalization; N/A, not applicable; neg, negative; SBO, small bowel obstruction.

the early 1990s. The result is a stage migration, with lower stages being discovered at the time of initial diagnosis (Lee et al, 2000). Thus, many individuals are advocating the use of nephron-sparing surgery (NSS) in patients with small renal tumors.

An extension of laparoscopy in the treatment of small renal lesions has been the partial nephrectomy, which mimics the fundamentals of open surgery. Tissue is removed under direct vision, with the margin status assessed intraoperatively. Direct vision and laparoscopic ultrasonography permit the laparoscopist to identify multifocal tumors, determine an adequate surgical margin, and maintain orientation with respect to the collecting system and renal hilum. If necessary, the collecting system can be resected with the surgical specimen to obtain adequate margins and then repaired. Endoscopic retrieval pouches allow removal of the tumor specimen without tumor spillage.

There are additional challenges associated with the laparoscopic approach, particularly related to hemostasis and closure of the collecting system. With open NSS, vascular occlusion can be used in conjunction with hypothermia (cold ischemia) to control bleeding during tumor resection and repair. Laparoscopic control has been reported but is a formidable and time-consuming task. Cold ischemia is difficult to accomplish laparoscopically, although there is a 1998 report of a cooling bag for laparoscopic use (Herrell et al, 1998). Given these obstacles, the emphasis has shifted away from vascular control at the renal hilum toward the development of techniques that allow simultaneous tumor resection and hemostasis. Electrocautery, the Cavitron ultrasonic surgical aspirator, the endovascular GIA stapler, the argon beam coagulator, topical agents, ultrasonic energy, microwave thermotherapy, and cable tie compression have all been used to decrease bleeding during tissue removal (Muraki et al, 1991; McDougall et al, 1993; Kagebayashi et al, 1995; Kletscher et al, 1995; Jackman et al, 1998; Naito et al, 1998; Yoshihiko et al, 1998; Harmon et al, 2000; Tanaka et al, 2000; Cadeddu and Corwin, 2001; Corwin and Cadeddu, 2001).

Primary closure of the urinary collecting system has been difficult to perform laparoscopically. In open NSS, a ureteral catheter that permits retrograde instillation of methylene blue can be placed to identify urinary extravasation. The collecting system is sutured primarily. In contrast, laparoscopic approaches have focused on the use of sealants to repair the collecting system. Hoznek and colleagues (1999) applied a biomixture of gelatin resorcinol and formaldehyde to the cut surface after excising lesions. In 13 patients, 2 developed postoperative urinomas, presumed

secondary to inadequate ureteral catheter drainage, although delayed failure of the sealant cannot be excluded. In their series of seven patients undergoing laparoscopic NSS, Janetschek and associates (1998) cauterized the bed of resection with the argon beam coagulator then sealed it with fibrin glue. None of the patients in their series were stented. Postoperatively, all patients had renal ultrasonography that demonstrated no urinary leakage.

Harmon and coworkers (2000) reported experience with laparoscopic NSS for solid renal masses in 15 patients (Table 103–8). The kidneys were fully mobilized to allow inspection of all renal parenchyma. Ultrasonic shears were used to divide the renal parenchyma, and hemostasis was accomplished with argon beam coagulation as well as oxidized regenerated cellulose gauze. Tumors were entrapped in an impermeable sack and removed intact for frozen section determination of their margin status. Laparoscopic NSS was successfully completed without complications in all patients. The mean tumor size was 2.3 cm (range 0.8 to 3.5 cm), the mean operative time was 170 minutes (range 105 to 240 minutes), and the mean estimated blood loss was 368 ml (range 75 to 1000 ml). Patients were hospitalized for a mean of 2.6 days (range 2 to 4 days). All surgical margins were negative, and the final lesion was renal cell carcinoma in 12 patients and oncocytoma in 3. At a mean follow-up of 14 months (range 3 to 24 months), no cases of tumor recurrence or port site seeding have been seen.

In a combined European series, Abbou and colleagues (2000) described 53 patients who underwent laparoscopic NSS for a renal mass less than 5 cm. Hemostasis was obtained at the time of wedge resection using bipolar coagulation and fibrin glue-coated cellulose. Thirty-five patients were found to have renal cell carcinoma. At a mean follow-up of 3 years, they reported a 100% disease-free survival rate.

Laparoscopic NSS for small solid renal masses can be performed safely utilizing innovative modalities to achieve hemostasis. This technique closely approximates the surgical goals of open NSS as an effective means of managing small renal tumors. Novel hemostatic techniques may allow increased applications.

LAPAROSCOPIC ABLATIVE TECHNIQUES

In an effort to further decrease morbidity, several new methods are being investigated to treat small renal lesions in situ. These techniques have the potential to minimize

blood loss, dissection, and complications when compared with extirpative approaches. Moreover, these modalities have the potential to be used in an image-guided manner to eliminate the need for surgical intervention. Cryotherapy, radiofrequency (RF) ablation, high-intensity focused ultrasonography, microwave therapy, and high-intensity radiation have all been investigated as tools to ablate renal tumors.

Cryosurgery

Cryotherapy has been one of the most studied ablative techniques. Multiple investigators have demonstrated the ability of temperatures of 20 C to induce tissue necrosis (Chosy et al, 1996; Campbell et al, 1998; Bishoff et al, 1999; Gill and Novick, 1999). Rapid freezing causes crystal formation in the microvasculature and extracellular spaces and within the cells. The latter results in uncoupling of oxidative phosphorylation and rupturing of plasma cell membranes with subsequent solute shifts. Progressive failure of the microvasculature results in endothelial cell damage, edema, and platelet aggregation with thrombosis and vascular occlusion (Bishoff et al, 1999).

Percutaneous, open, and laparoscopic approaches have all been utilized in cryoablation. Adequate cryodestruction requires intraoperative monitoring of the resultant "ice-ball." To date, CT and MRI have not proved to be reliable modalities for detecting the progression of the ice-ball. On ultrasonography, however, the cryoablated region appears hypoechoic and demonstrates a loss of normal flow characteristics on color-flow Doppler that closely approximates the size and location of the ice-ball (Delworth et al, 1996; Campbell et al, 1998; Bishoff et al, 1999; Gill and Novick, 1999). **Laparoscopy permits the use of intraoperative laparoscopic ultrasonography to monitor the progression of the ice-ball. Campbell and associates (1998) demonstrated that the ice-ball visualized on intraoperative laparoscopic ultrasonography must extend at least 3.1 mm beyond the outer edge of the renal lesion of interest in order to ensure that a temperature of 20 C is reached in the tissues farthest from the cryoprobe.** Larger lesions would therefore require multiple passes with multiple probes to achieve adequate ablation.

Microscopic examination of the ablation site immediately after the procedure demonstrates extensive hemorrhage into the glomerular and tubular urinary spaces. One week after cryosurgery, the lesion reflects four distinct histological zones from the center: (1) complete necrosis, (2) inflammatory infiltrate, (3) hemorrhage, and (4) fibrosis and regeneration. By 13 weeks, these zones are replaced by fibrous connective tissue with occasional necrotic cellular debris (Bishoff et al, 1999). The cryotherapy literature lacks definitive evidence that the size of the ice-ball visualized during cryoablation corresponds precisely with the histopathologic changes described.

Potential complications of cryosurgery include urinary fistula formation, post-treatment hemorrhage, and injury to adjacent structures to include the collecting system, bowel, and liver. Given that even momentary contact of the active cryoprobe can lead to necrosis and

fibrosis, disastrous results could soon follow (Campbell et al, 1998). **Bishoff and coworkers (1999) in a porcine model noted severe adhesions between cryoablated kidney and overlying bowel in non-retroperitonealized kidneys. There was no evidence of bowel injury or fistulas. Gill and colleagues (1999) reported the complication of small bowel obstruction when the cryoprobe inadvertently contacted a loop of small bowel during porcine laparoscopic renal cryoablation.** Campbell and associates (1998) described an obstructive stricture of the ureteropelvic junction.

To date, there are only limited short-term clinical trials assessing the efficacy of cryoablation in select patients. Rodriguez and colleagues (2000) performed the procedure in eight patients with small (mean 2-cm) renal tumors. At 9 months of follow-up, they identified one patient with an enhancing lesion in the area of cryoablation that was a biopsy-proven renal cell recurrence. Levin and associates (2000), who performed laparoscopic cryoablation in 39 patients, reported one patient with a recurrence at 9 months. Shingleton and coworkers (2000) performed percutaneous MRI-guided cryoablation in 17 patients with 18 renal tumors; one tumor required retreatment due to an enhancing portion of the tumor on 1-month CT scans. These reports of short-term local recurrences mandate further investigation to predict cryotherapy's ultimate role in the treatment of renal tumors.

Radiofrequency Interstitial Tissue Ablation

RF ablation has been utilized in a number of different clinical applications, including ablation of cardiac dysrhythmias and treatment of lesions arising from the liver, nervous system, and bone (Zlotta et al, 1997; Dupuy, 1999; McGovern et al, 1999; Nakada, 1999; Crowley and Bishoff, 2000). Urologists have used this technology to treat benign prostatic hypertrophy through a transurethral approach.

The RF energy can be introduced percutaneously, laparoscopically, or through an open approach under ultrasonographic, fluoroscopic, CT, or MRI guidance. The RF energy returns to the RF generator by way of a grounding pad that completes the electric circuit. **The probe carries an alternating current of high-frequency radiowaves that causes the local ions to vibrate, and the resistance in the tissue creates heat to the point of desiccation (thermal coagulation).** Microscopic examination reveals intense stromal and epithelial edema with marked hypereosinophilia and pyknosis immediately after RF treatment (Zlotta et al, 1997). **This is replaced in a matter of days to weeks by coagulative necrosis with concentric zones of inflammatory infiltrate, hemorrhage, and fibrosis** (Crowley et al, 2000).

Precise control of the size of the lesion can be achieved by temperature-based or impedance-based monitoring. Temperature-based systems depend on thermocouples imbedded within the tips of the electrodes. Sufficient amounts of RF energy (10 to 90 W) are applied to raise the tissue temperature to the minimal 60 C required to induce coagulative necrosis (Crowley et al, 2000). However, the observation that temperatures recorded at the limit of ablation

have been found to be 20 C to 30 C cooler than temperatures recorded at the thermocouples makes sufficient tissue desiccation uncertain. For this reason, some authors favor an impedance-based system, which applies RF energy through the electric circuit until the tissue becomes sufficiently desiccated to become an insulator. In this manner, the flow of RF energy back to the return pad is blocked. A gradual decrease in tissue impedance suggests that the thermal lesion is continuing to evolve; a rise in impedance (to approximately 200 Ω) suggests that the tissue is desiccated and that further thermal lesion growth is unlikely (Lewin et al, 1998).

Although ultrasonography, fluoroscopy, CT, and MRI have all been used for positioning of the patient and for percutaneous placement of the RF probe, none of these modalities has proved reliable for the intraoperative monitoring of the RF lesion. On ultrasound imaging, there is no immediate change in the echotexture in the area of RF ablation, and color and power Doppler ultrasonography are of no added benefit because of variable and inconsistent findings (Crowley et al, 2000). Moreover, RF treatment can sometimes disturb ultrasound imaging (Zlotta et al, 1997).

Crowley and colleagues (2000) found CT to be excellent for positioning of the patient and probe and for immediate post-treatment imaging, but it was not utilized for intraoperative monitoring. Lewin and associates (1998) used MRI to monitor real-time tissue destruction with RF ablation. This group demonstrated a zone of decreased signal surrounded by a rim of hyperintensity on T₂-weighted and STIR (turbo short inversion-time inversion recovery) images. However, confirmatory images obtained after conclusion of the ablation session revealed a propensity for these T₂-weighted images to underestimate the size of the RF lesion. Thus, insofar as intraoperative monitoring for RF intensity is concerned, there is no imaging modality that can in real time ensure a sufficient extent of tissue ablation while avoiding injury to normal adjacent parenchyma.

Walther and coworkers (2000) explored 14 tumors less than 5 cm in four patients with multiple renal lesions and performed RF ablation just before surgical excision. A complete immediate treatment effect was noted in 10 of 11 patients; in the final case, only 35% of the tumor was ablated. Excluding any technical inconsistencies, as with the early results of cryoablation, this early treatment failure needs to be put into the context of long-term, prospective clinical trials.

COMPLICATIONS OF LAPAROSCOPIC RENAL SURGERY

Complications are an unavoidable consequence of surgical practice. Even when the surgery is in the most experienced hands, factors related to the patient, operating room environment, and chaotic forces can lead to an untoward event. Thus, efforts at prevention and the patients' understanding should be maximized. Moreover, if complications occur, the consequences can often be minimized through early recognition and appropriate intervention.

Laparoscopic renal surgery shares several potential risks with traditional open approaches; however, there are differences in the type and presentation of these complications.

It must be kept in mind that all situations are individual, and unique problems may arise requiring innovative actions.

Complications can arise during each step of the laparoscopic nephrectomy. Access-related problems such as solid organ injury, bowel injury, abdominal wall hematoma, and epigastric vessel injuries have been reported. **Bleeding complications can be minimized by carefully inspecting the abdomen at the conclusion of surgery. Examination after lowering the intra-abdominal pressure can reveal venous bleeders tamponaded by the pneumoperitoneum. One also needs to carefully inspect the area of surgical dissection and the trocar sites for adequate hemostasis. Common areas of postoperative intra-abdominal bleeding include the adrenal gland, mesentery, gonadal vessels, and ureteral stump.**

Another potential problem in patients undergoing laparoscopic renal surgery is volume overload. In the laparoscopic approach, patients have less insensible fluid loss compared with their open surgical counterparts. There is also a vascular-mediated oliguria that should not be aggressively treated because diuresis is seen after release of the pneumoperitoneum. Volume overload in patients with diminished cardiac reserve can result in congestive heart failure manifested by oliguria. Poor urine output or hemodynamic instability in the postoperative period should initiate an evaluation to rule out bleeding; if the work-up is negative, diuresis can be induced if clinically indicated.

Additionally reported common complications include incisional hernia after intact specimen removal, transient thigh numbness, prolonged ileus, pulmonary embolus, pneumonia, brachial nerve injury, and unrecognized bowel injury (Copcoat et al, 1992; Kavoussi et al, 1993; Kerbl et al 1993a, 1993b, 1994a, 1994b; Rassweiler et al, 1993, 1996; Eraky et al, 1994; Nicol et al, 1994; Perez et al, 1994; Parra et al, 1995; Keeley and Tolley, 1998; Rozenberg et al, 1999).

Unrecognized bowel injury is a potential complication of any transabdominal or retroperitoneal surgical procedure. During open surgery, bowel injuries are usually recognized and treated at the time of the procedure. **One of the most devastating complications occurring as a result of laparoscopic surgery is unrecognized bowel injury. Because only 10% of the laparoscopic instrument is in the visual field, these injuries can occur out of the surgeon's field of view. The combined incidence of bowel injury in the literature is 1.3 in 1000 cases (Bishoff et al, 1999). Most injuries (69%) are not recognized at the time of surgery. Small bowel segments account for 58% of injuries followed by colon (32%) and stomach (7%). Fifty percent of bowel injuries are caused by electrocautery, and 32% occur during Veress needle or trocar insertion.**

The presentation of bowel injuries in the laparoscopic group differs from that described with open postoperative injury with peritonitis. Patients with unrecognized bowel injury after laparoscopy typically present with persistent and increased trocar site pain at the site closest to the bowel injury. Later signs and symptoms include nausea, diarrhea, anorexia, low-grade fever, persistent bowel sounds, and a low or normal white blood cell count. The patient's condition can rapidly deteriorate to hemodynamic instability and death if the injury

is not quickly recognized and treated. CT is the initial diagnostic modality of choice (Cadeddu et al, 1997), and open exploration is usually required to evacuate bowel spillage and perform the necessary repair.

Complication rates have been reported in several large multi-institutional reviews of laparoscopic simple nephrectomy. In a series of 185 patients, Gill and coworkers (1995) reported an overall complication rate of 12% for benign disease, with 5% of patients requiring conversion to open surgery. In their series, the incidence of complications decreased markedly with increasing experience. **In fact, 70% of the complications occurred during the first 20 cases at each institution. A learning curve of approximately 20 laparoscopic nephrectomy cases is also supported by other reports** (Keeley and Tolley, 1998; Rassweiler et al 1998; Fahlenkamp et al, 1999).

Rassweiler and colleagues (1998) published the results of a series of 482 laparoscopic nephrectomies (444 procedures for benign disease) performed by 20 surgeons at 14 different European medical centers. They reported a 6% overall complication rate, with 10% of the cases converted to open surgery. **The majority of patients converted to open surgery had infectious causes of renal abnormality as the leading indication for kidney removal. Bleeding was the most common cause of open conversion, followed by the surgeon's inability to visualize the renal hilum for dissection.**

Gupta and associates (1999) presented a series of 126 laparoscopic nephrectomies performed for benign disease. In their series, 12% (15 of 126) of the patients required conversion to an open surgical procedure. The overall incidence of major and minor complications was 17% (22 of 126).

In 1998, Cadeddu and colleagues reported a minor and major complication rate of 9.6% in a series of 157 laparoscopic radical nephrectomies. **In a contemporary comparison of laparoscopic and open radical nephrectomy, Chan and associates (2000) found no difference in the number and severity of complications.**

CONCLUSIONS

Laparoscopy has emerged as a powerful minimally invasive surgical tool to treat renal lesions. In a wide variety of applications, patients benefit from decreased morbidity without sacrificing therapeutic outcomes. Unfortunately, the availability of laparoscopic renal surgery is limited.

Laparoscopic skill requires intensive training and frequent practice to maintain proficiency. Unlike the situation in the fields of general surgery and gynecology, there is no simple, frequently performed urologic procedure that allows most urologic surgeons the opportunity to sustain laparoscopic skills. Weekend courses and occasional cases are not sufficient to impart the necessary expertise to surgeons.

For laparoscopy to become an integral part of mainstream urology, changes in education and advances in technology are needed. Large community groups and academic practices need to identify select urologic surgeons to train in laparoscopic approaches. These individuals need to be

supported through case referrals to maintain operative proficiency. Novel methods of mentoring and monitoring progress through the use of telecommunication technologies need to be developed. Continued advances in suturing, stapling, and robotic and imaging modalities will help shorten the learning curve associated with this new skill and increase patients' access to the benefits offered by laparoscopic surgery.

Laparoscopic surgery represents a significant advance in the surgical treatment of renal abnormalities; however, this access technique is but a stepping stone in the evolution of surgery. Early results with ablative techniques hold promise for eventual nonoperative management of most renal lesions.

REFERENCES

Historical Overview

- Baba S, Nakagawa K, Nakamura, et al: Experience of 143 cases of laparoscopic surgery in urology—clinical outcome in comparison to open surgery. *Jpn J Urol* 1996;87:842–850.
- Clayman RV, Kavoussi LR, Soper NJ, et al: Laparoscopic nephrectomy: Initial case report. *J Urol* 1991;146:278–282.
- Copcoat MJ, Joyce AJ, Popert R, et al: Laparoscopic nephrectomy—the King's experience. *Minim Invasive Ther* 1992;1(Suppl):67.
- Doublet JD, Barreto HS, Degromont AC, et al: Retroperitoneal nephrectomy: Comparison of laparoscopy with open surgery. *World J Surg* 1996;20:713–716.
- Griffith DO, Schussler WW, Vancaille TH: Laparoscopic lymphadenectomy: A low morbidity alternative for staging pelvic malignancies. *J Endourol* 1990;4:S84.
- Hemal AK, Talwar M, Wadhwa SN, Gupta NP: Retroperitoneoscopic nephrectomy for benign diseases of the kidney: Prospective nonrandomized comparison with open surgical nephrectomy. *J Endourol* 1999;13:425–431.
- Kavoussi LR, Kerbl K, Capelouto CC, et al: Laparoscopic nephrectomy for renal neoplasms. *Urology* 1993;42:603–609.
- Kerbl K, Clayman RV, McDougall EM, Kavoussi LR: Laparoscopic nephrectomy: Current status. *Arch Esp Urol* 1993a;46:581–584.
- Kerbl K, Clayman RV, McDougall EM, Kavoussi LR: Laparoscopic nephrectomy. *BMJ* 1993b;307:1488–1489.
- Kerbl K, Clayman RV, McDougall EM, et al: Transperitoneal nephrectomy for benign disease of the kidney: A comparison of laparoscopic and open surgical techniques. *Urol* 1994;43:607–613.
- Nicol DL, Winkle DC, Nathanson LK, Smithers B: Laparoscopic nephrectomy for benign disease. *Br J Urol* 1994;73:237–241.
- Perez MG, Parra RO, Boullier JA, et al: Comparison between standard flank versus laparoscopic nephrectomy for benign renal disease. *J Urol* 1994;2:151 667a.
- Rassweiler JJ, Henkel TO, Stock C, et al: Transperitoneal and retroperitoneal laparoscopic nephrectomy: Indications and results. *J Endourol* 1993;7:S175.
- Rassweiler JJ, Frede T, Henkel TO, et al: Nephrectomy: A comparative study between the transperitoneal and retroperitoneal laparoscopic versus the open approach. *Eur Urol* 1998;33:489–496.
- Rassweiler JJ, Stock C, Frede T, et al: Transperitoneal and retroperitoneal laparoscopic nephrectomy in comparison with conventional nephrectomy. *Urologe A* 1996;35:215–222.
- Rozenberg H, Bruyere F, Abdelkader T, et al: Transperitoneal laparoscopic nephrectomy. *Prog Urol* 1999;9:1034–1038.

Patient Evaluation and Preparation

- Adams JB, Marco AD, Averch TD, et al: Physiologic changes during laparoscopy utilizing 20 mm Hg intra-abdominal pressure. *J Endourol* 1995;9:S152.
- Arthur H: Laparoscopy hazard. *BMJ* 1970;4:492.
- Bishoff JT, Allaf ME, Kirkels W, et al: Laparoscopic bowel injury: Incidence and clinical presentation. *J Urol* 1999;3:887–891.
- Cadeddu JA, Chan DY, Hedicani, et al: Retroperitoneal access for trans-